

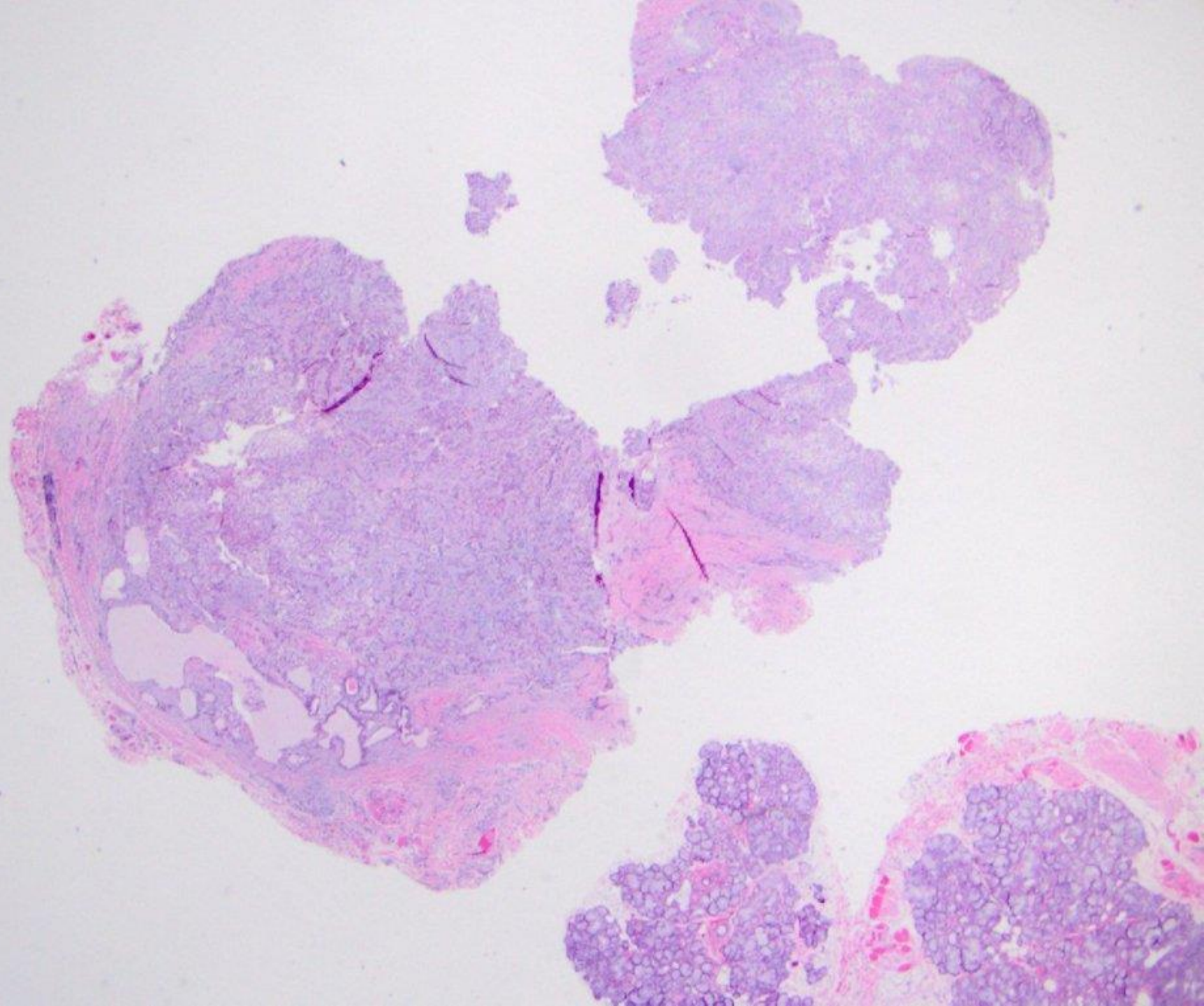
Oral Histopathology

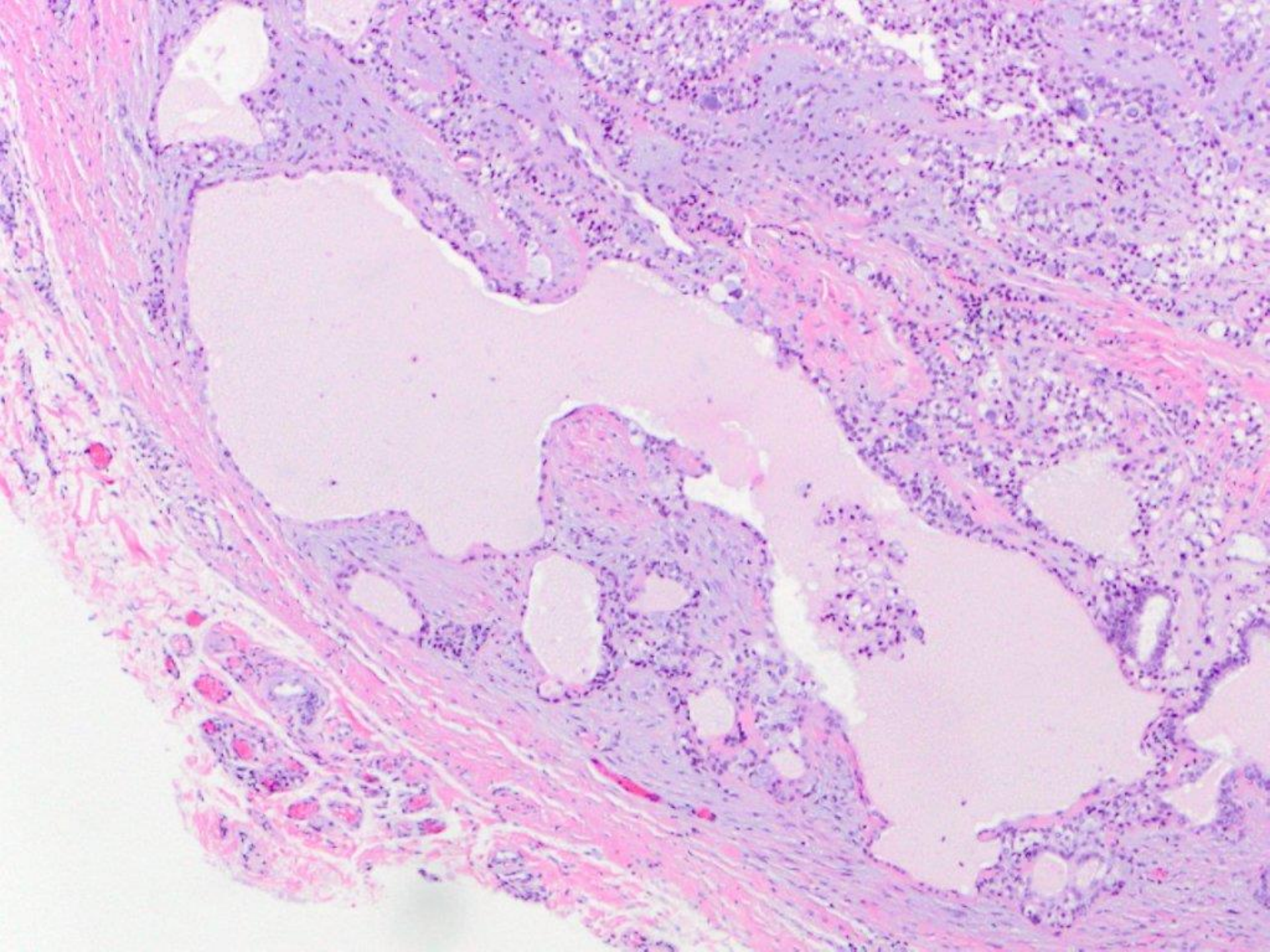
Series 39

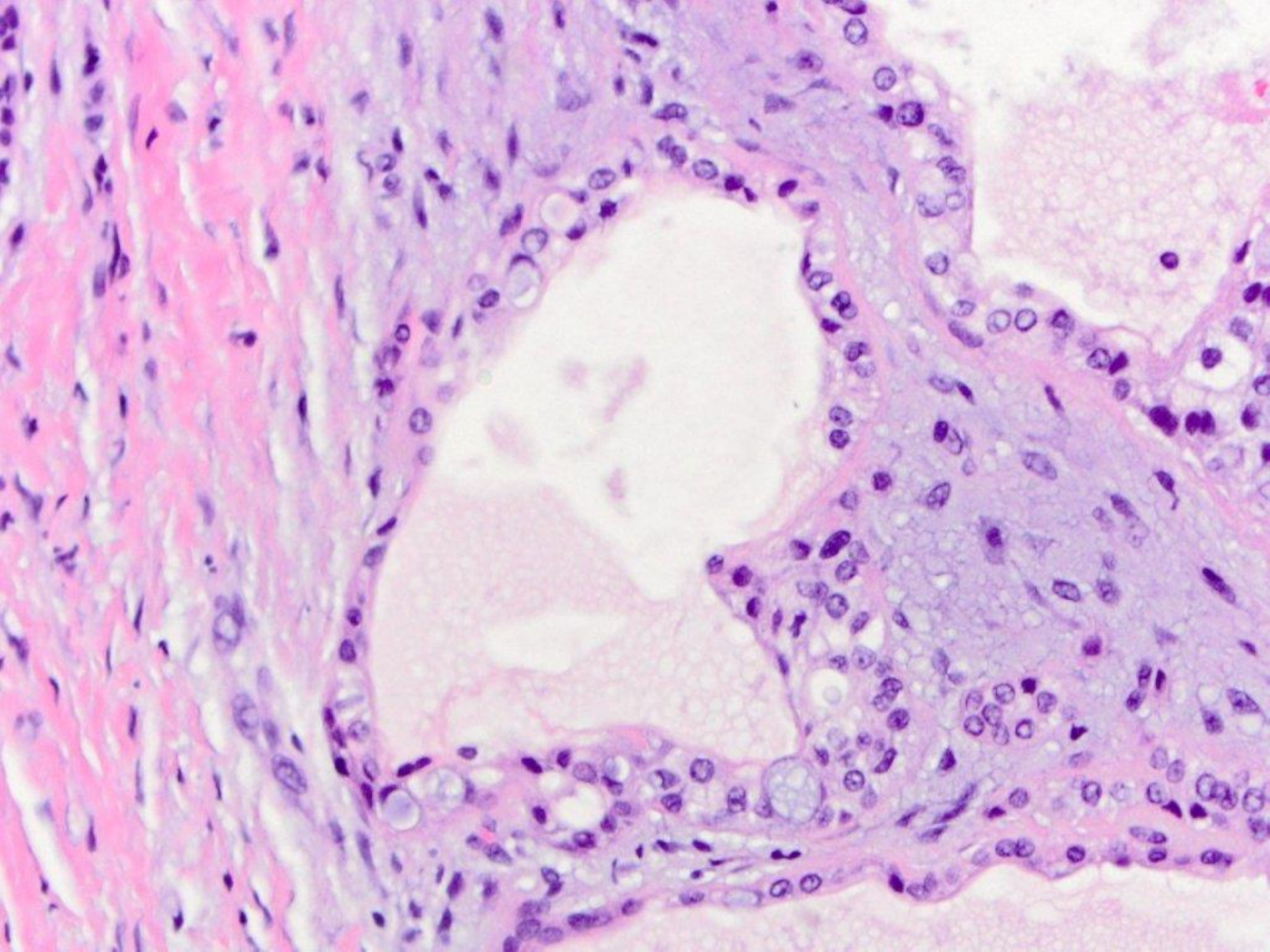
DAVID E. KLINGMAN, DMD

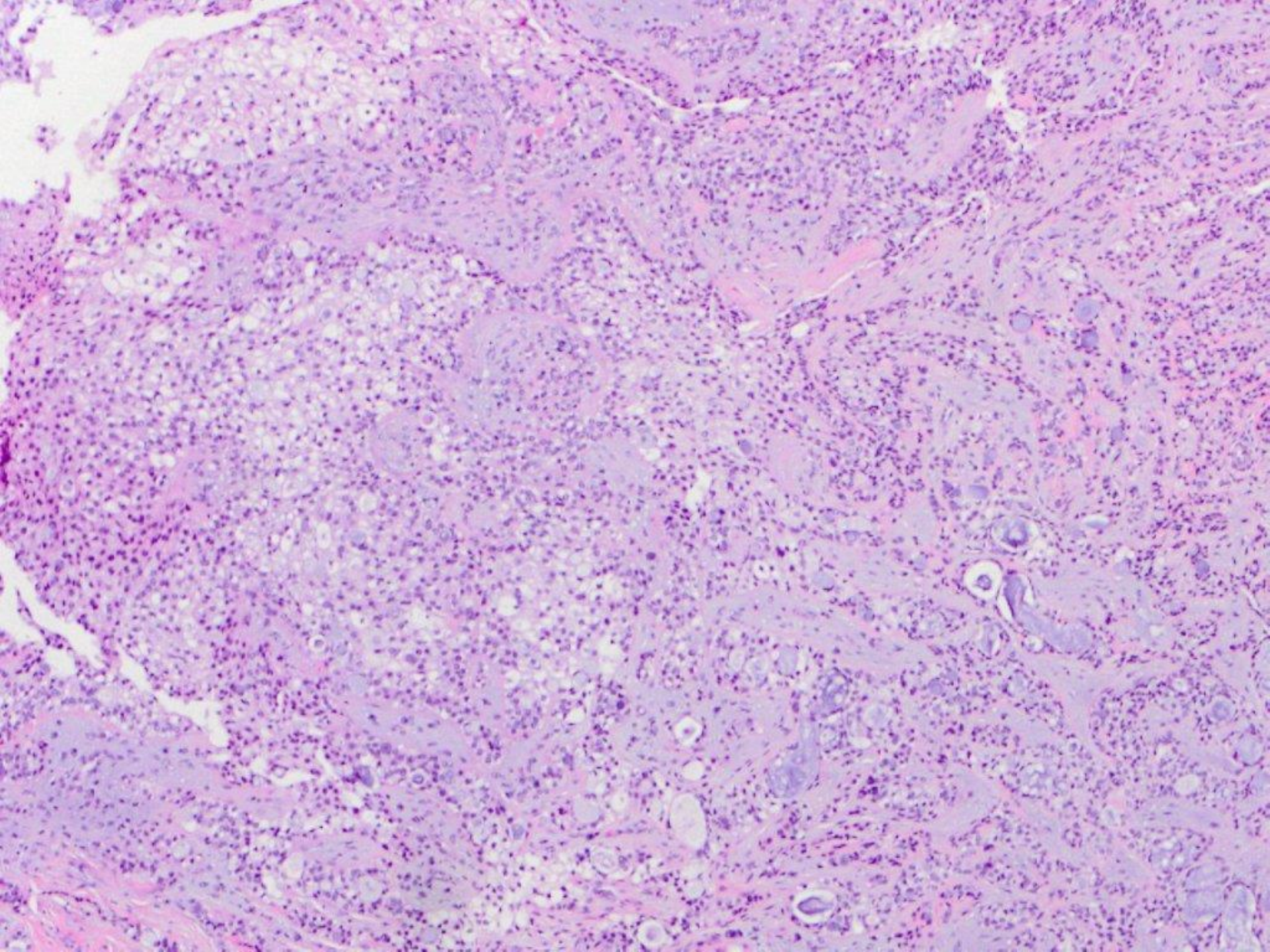
Diplomate, American Board of Oral and Maxillofacial Pathology

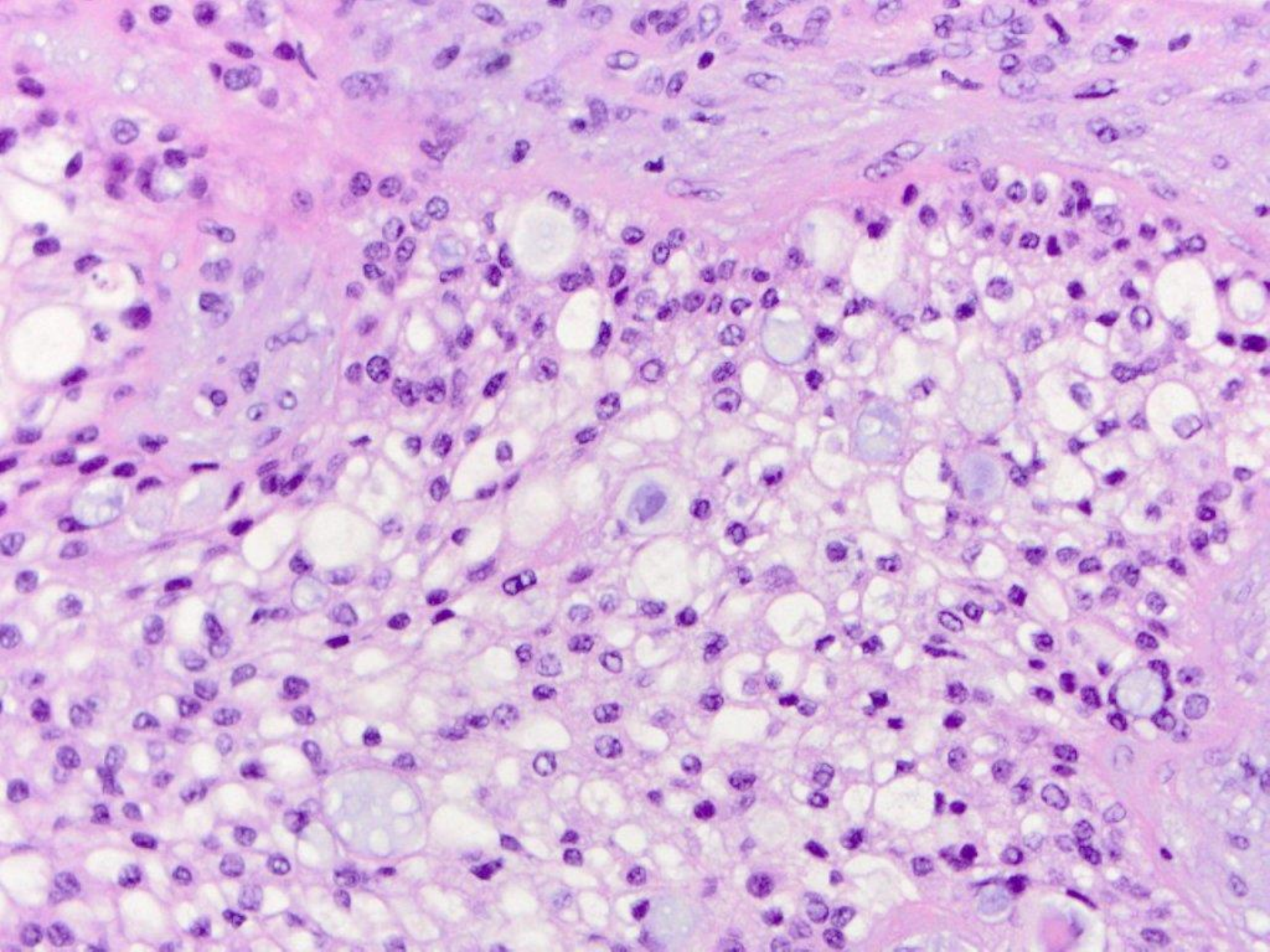
Diplomate, American Board of General Dentistry

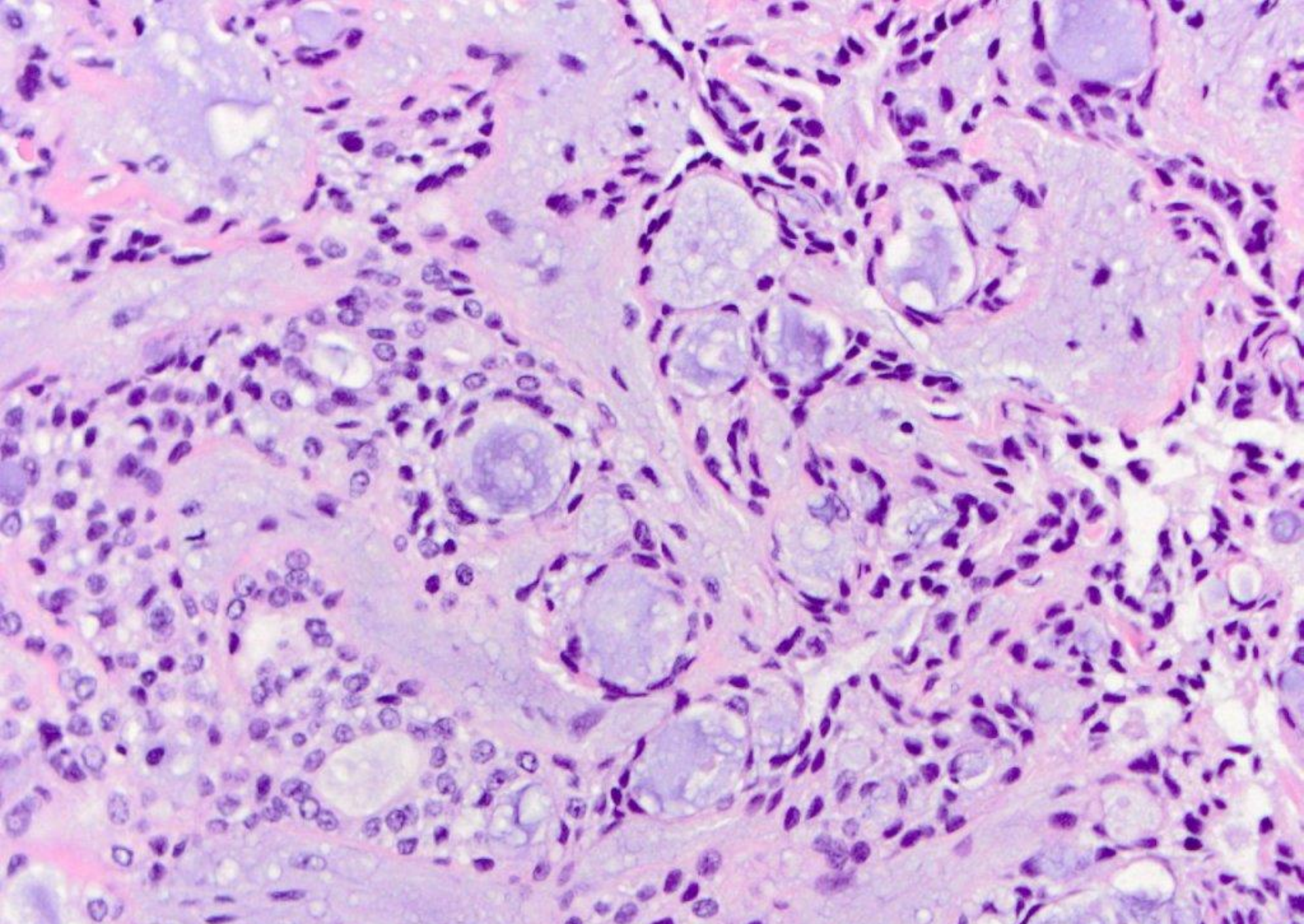




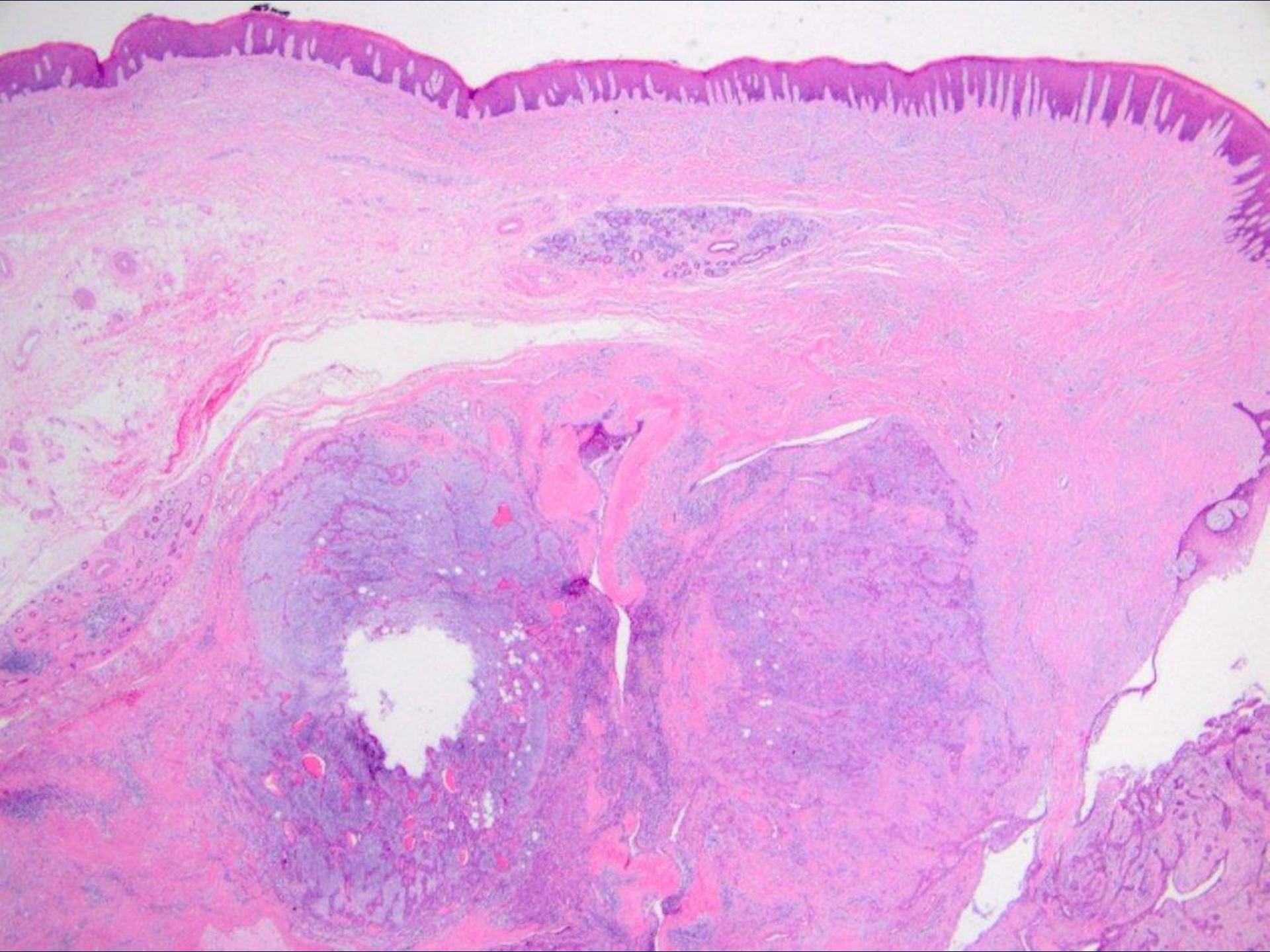


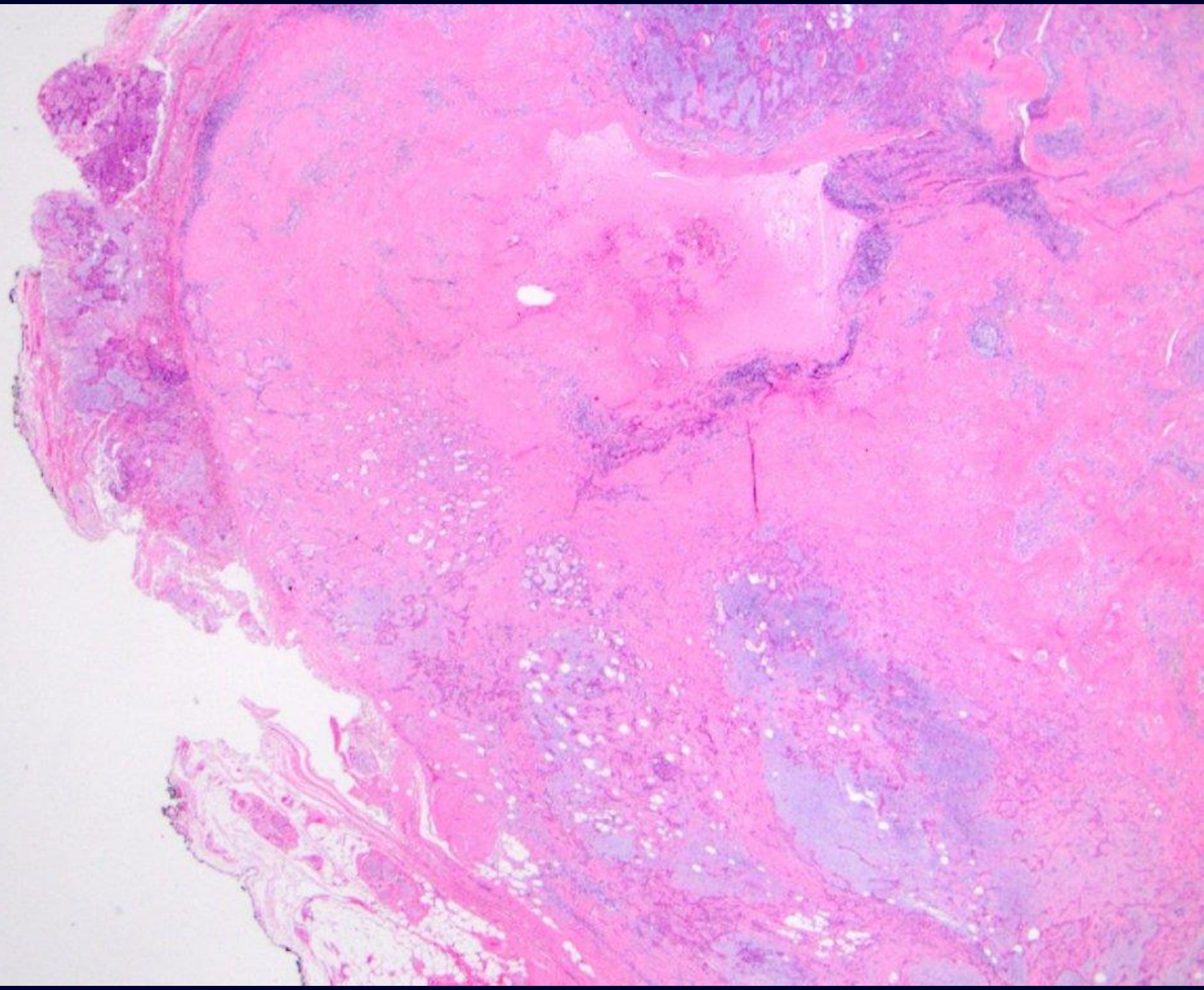


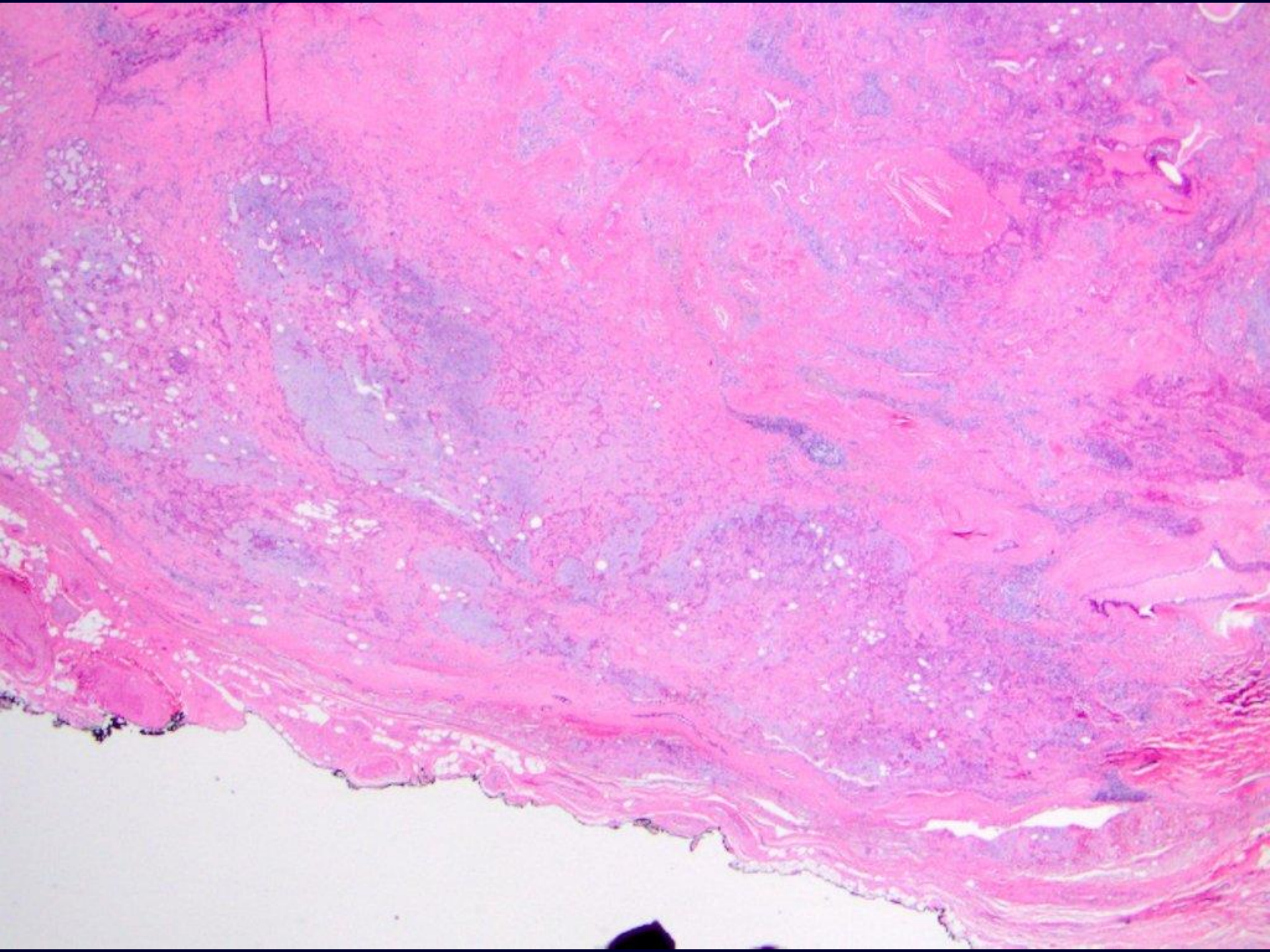


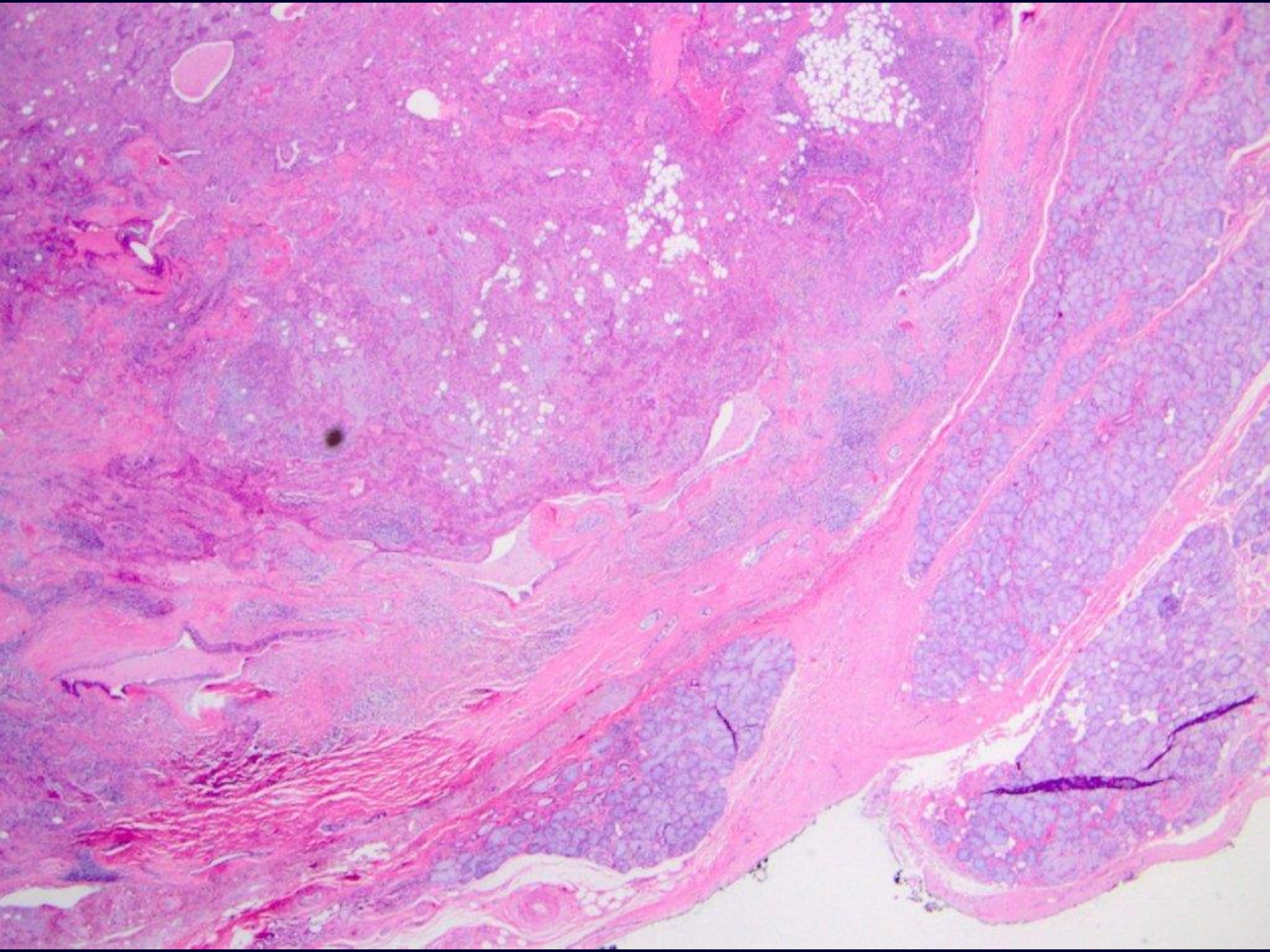


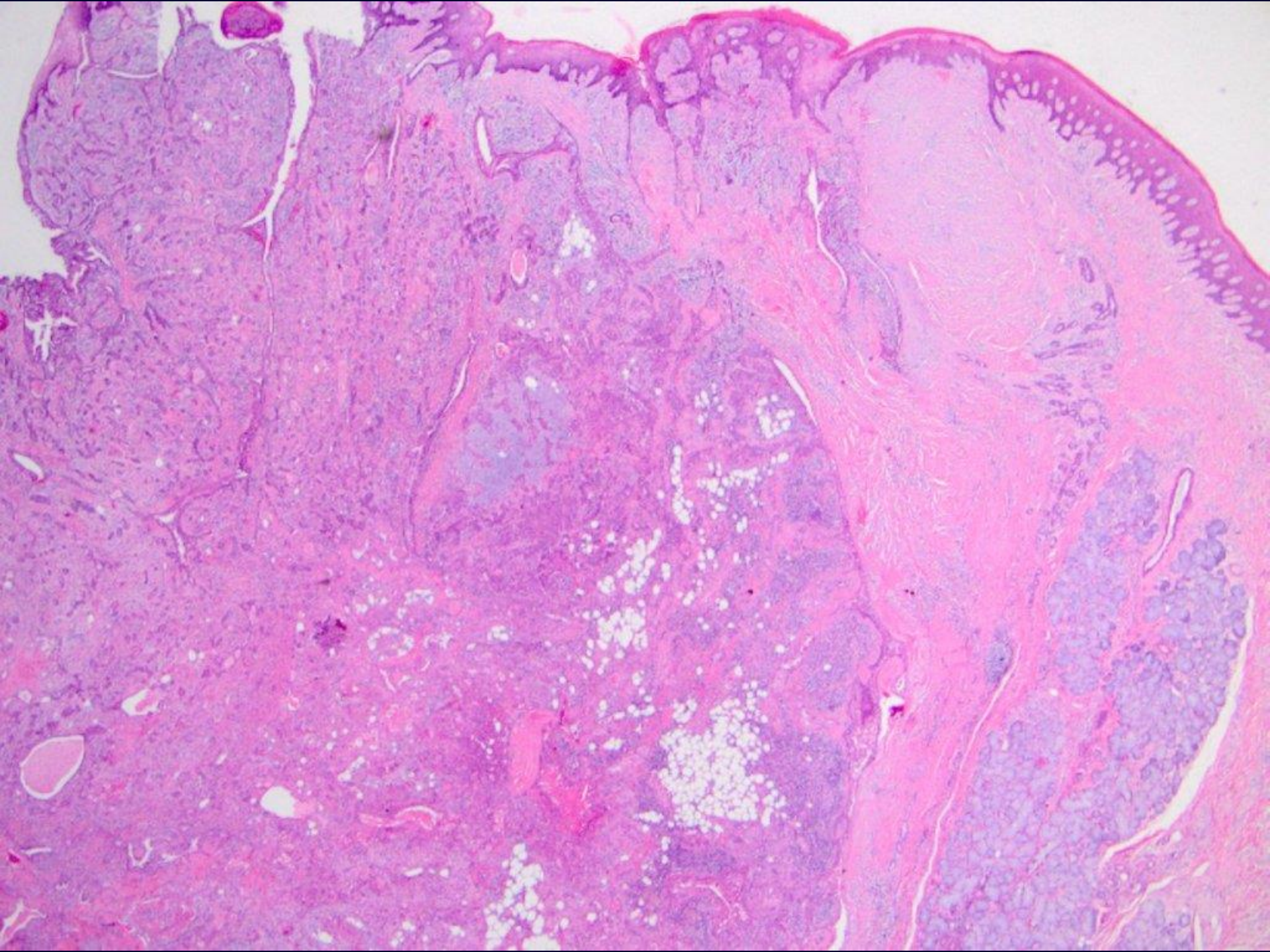
mucoepidermoid carcinoma, low grade

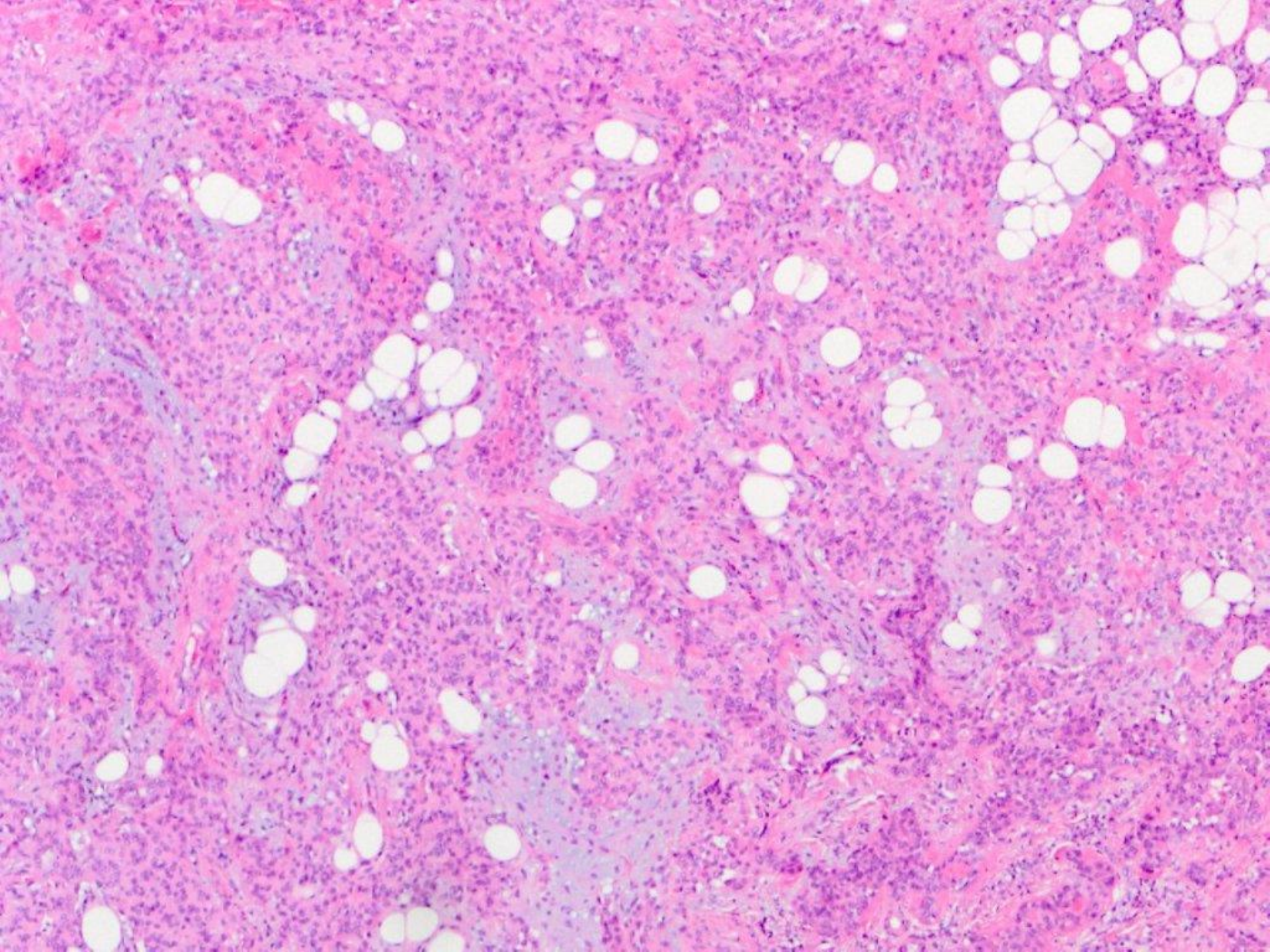


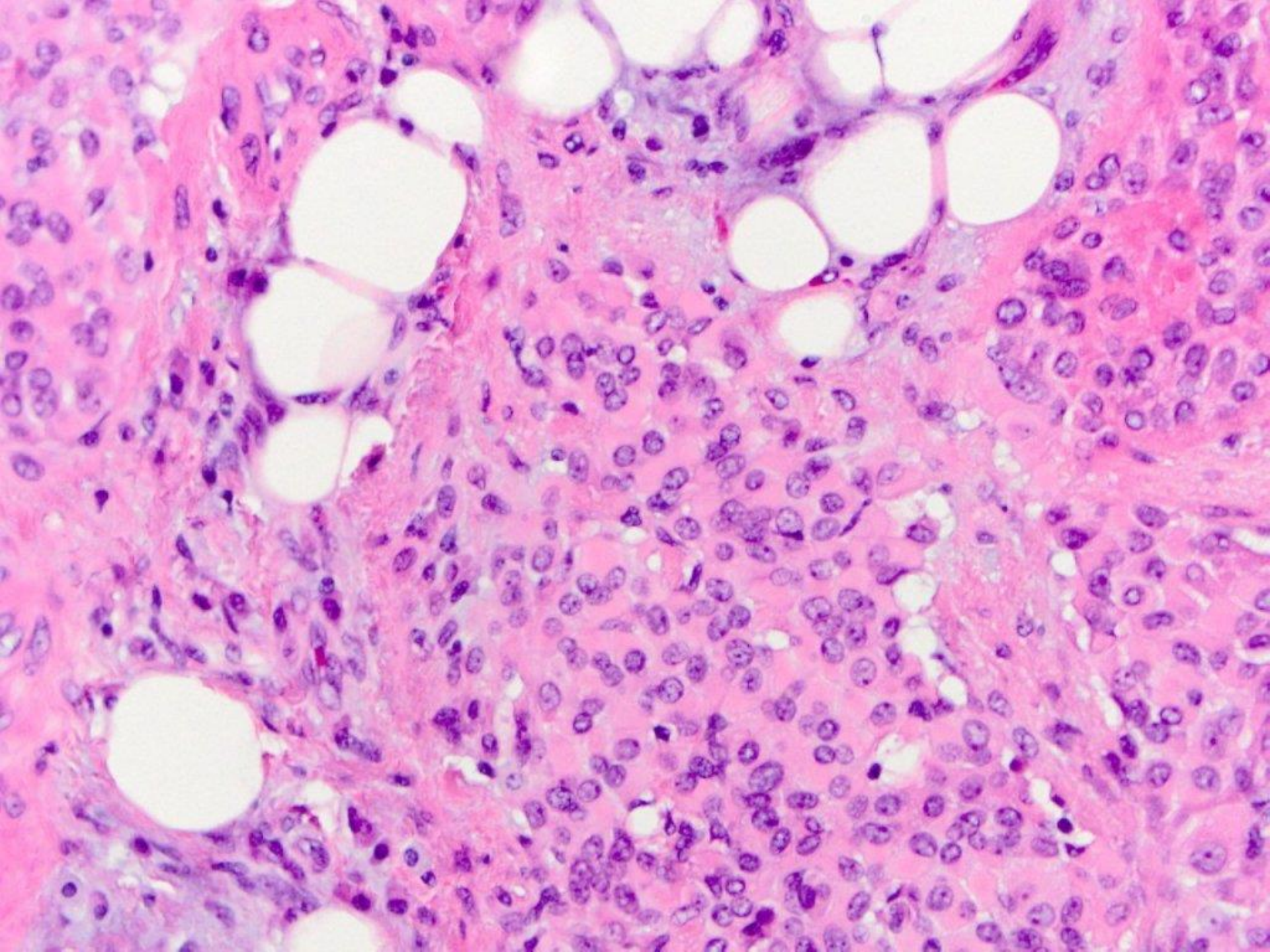


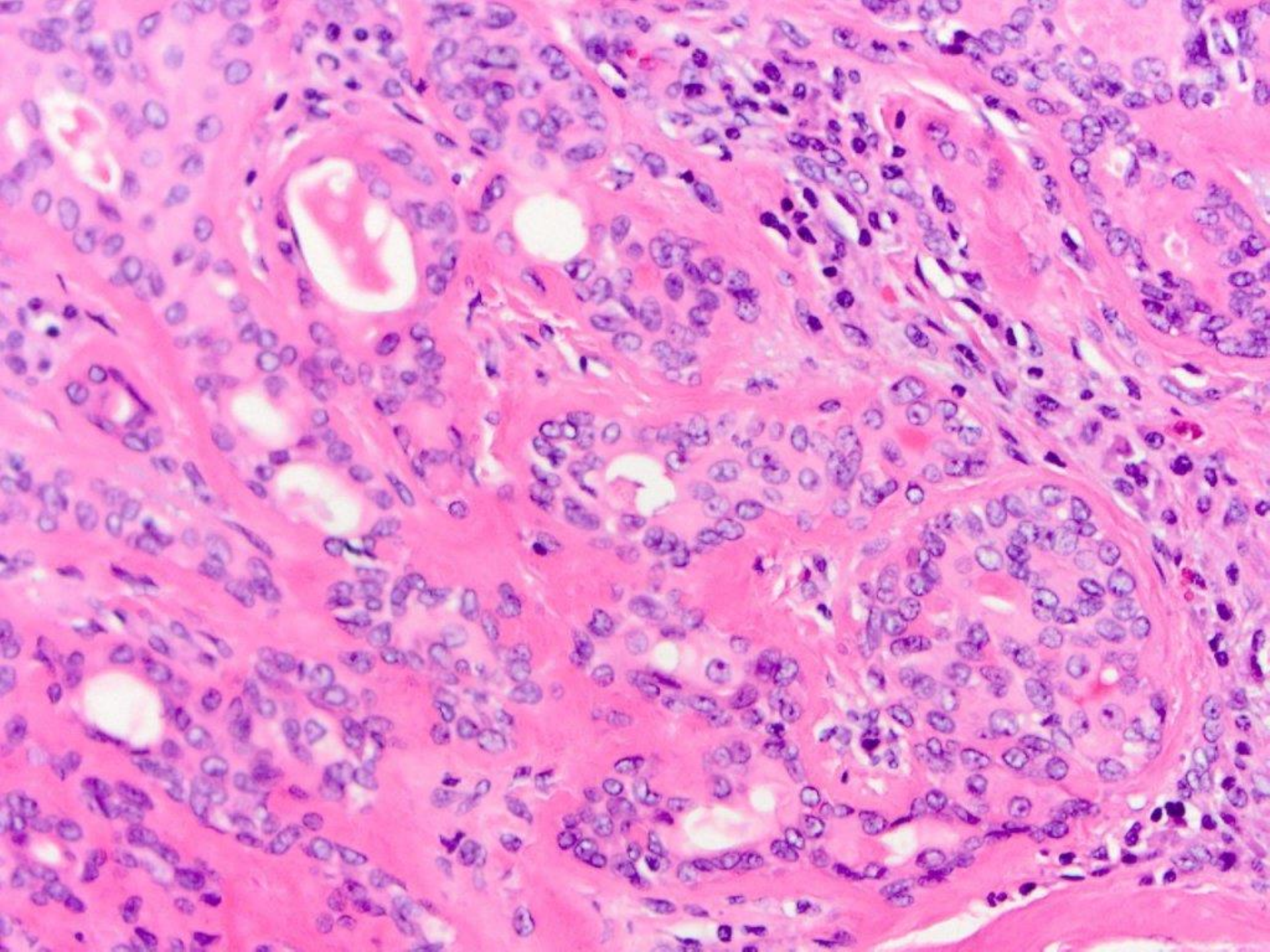


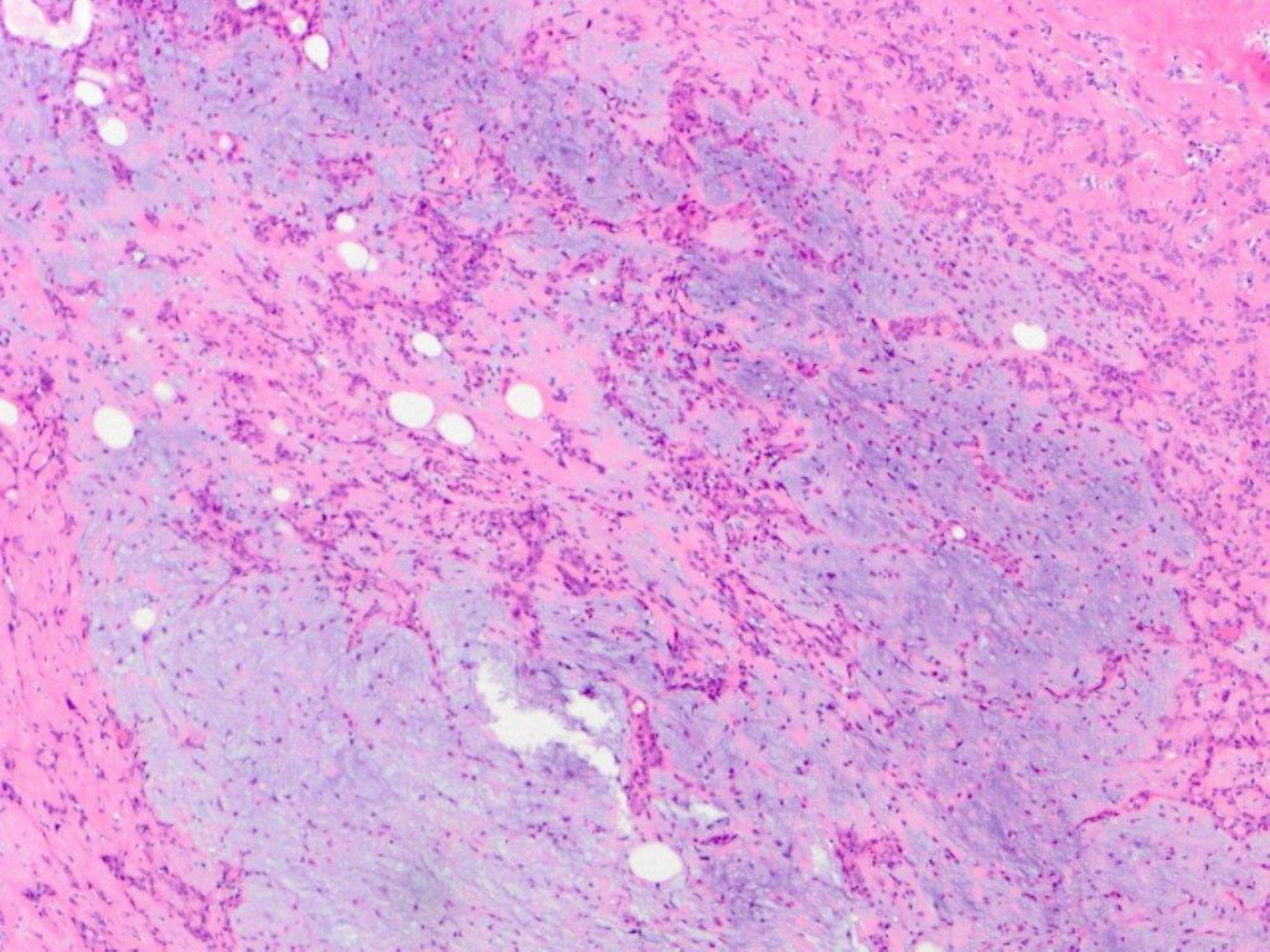


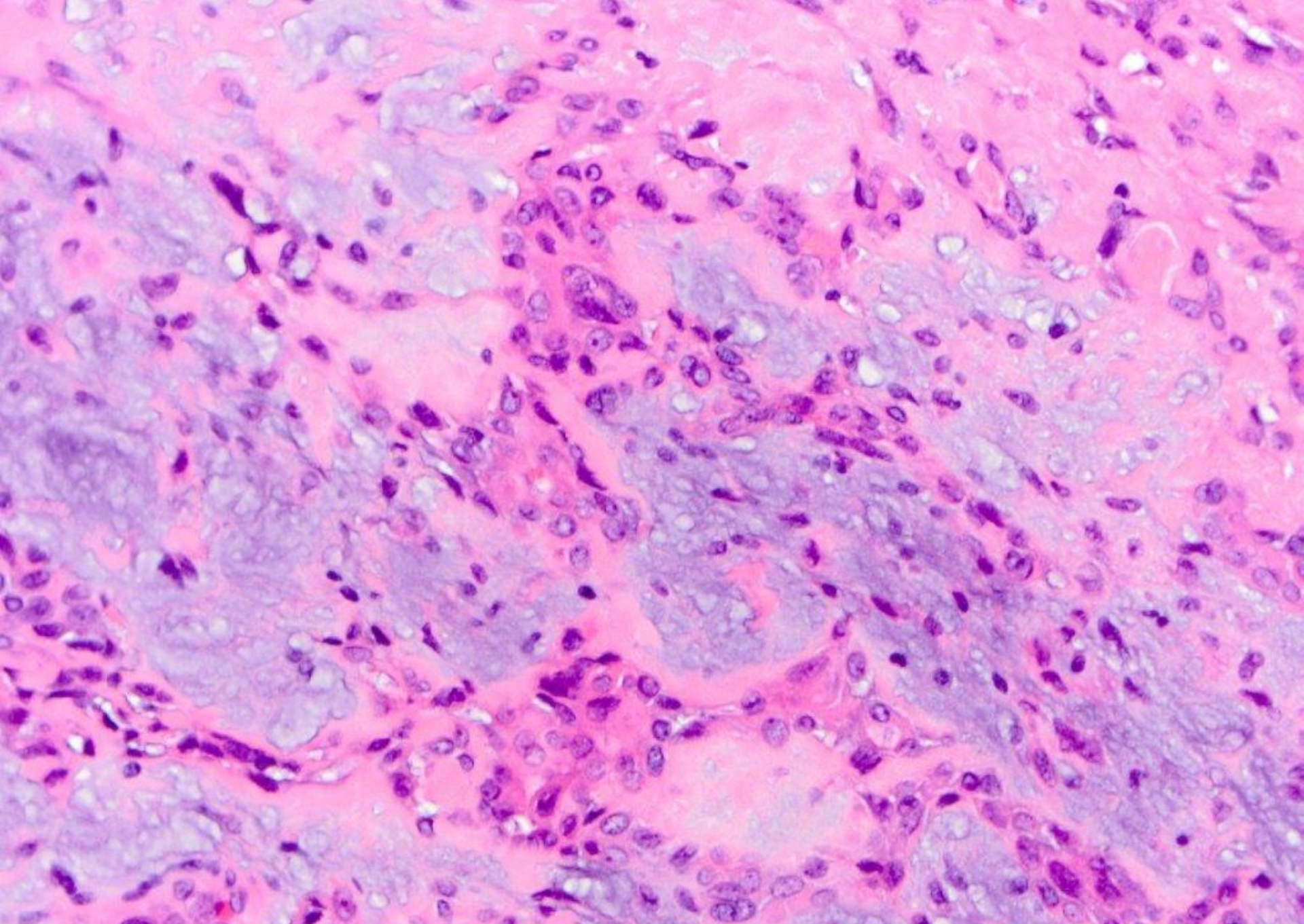




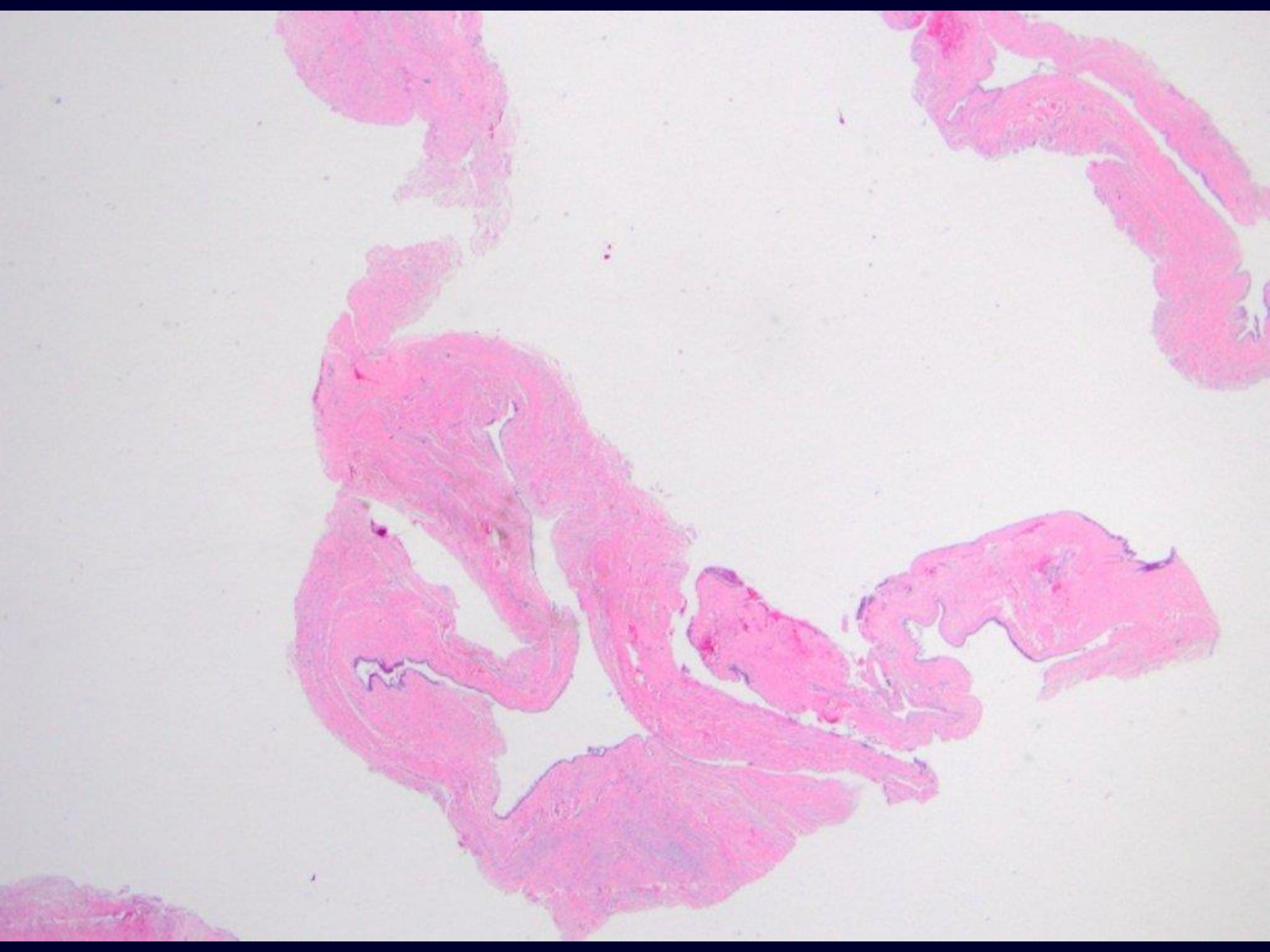


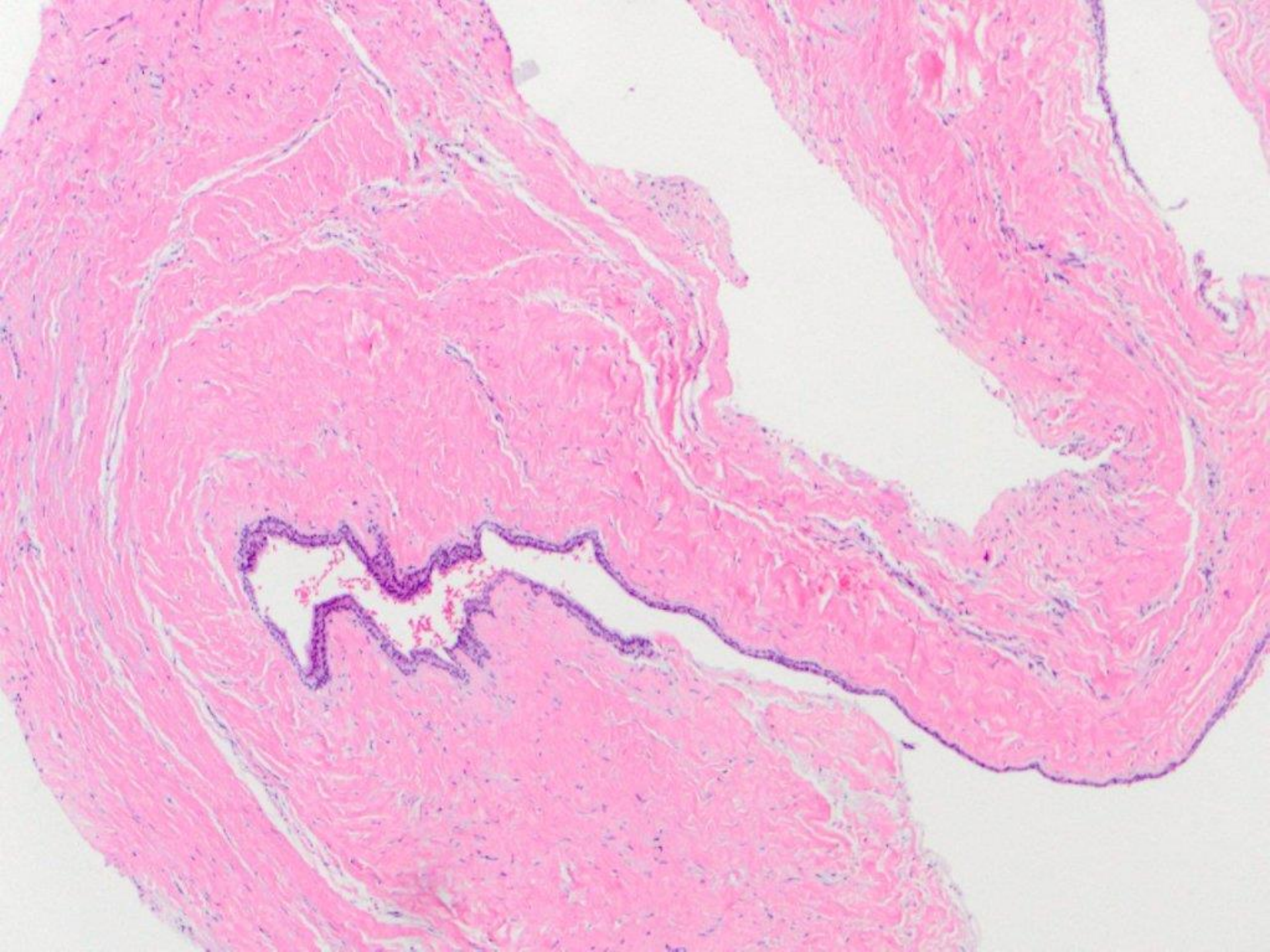


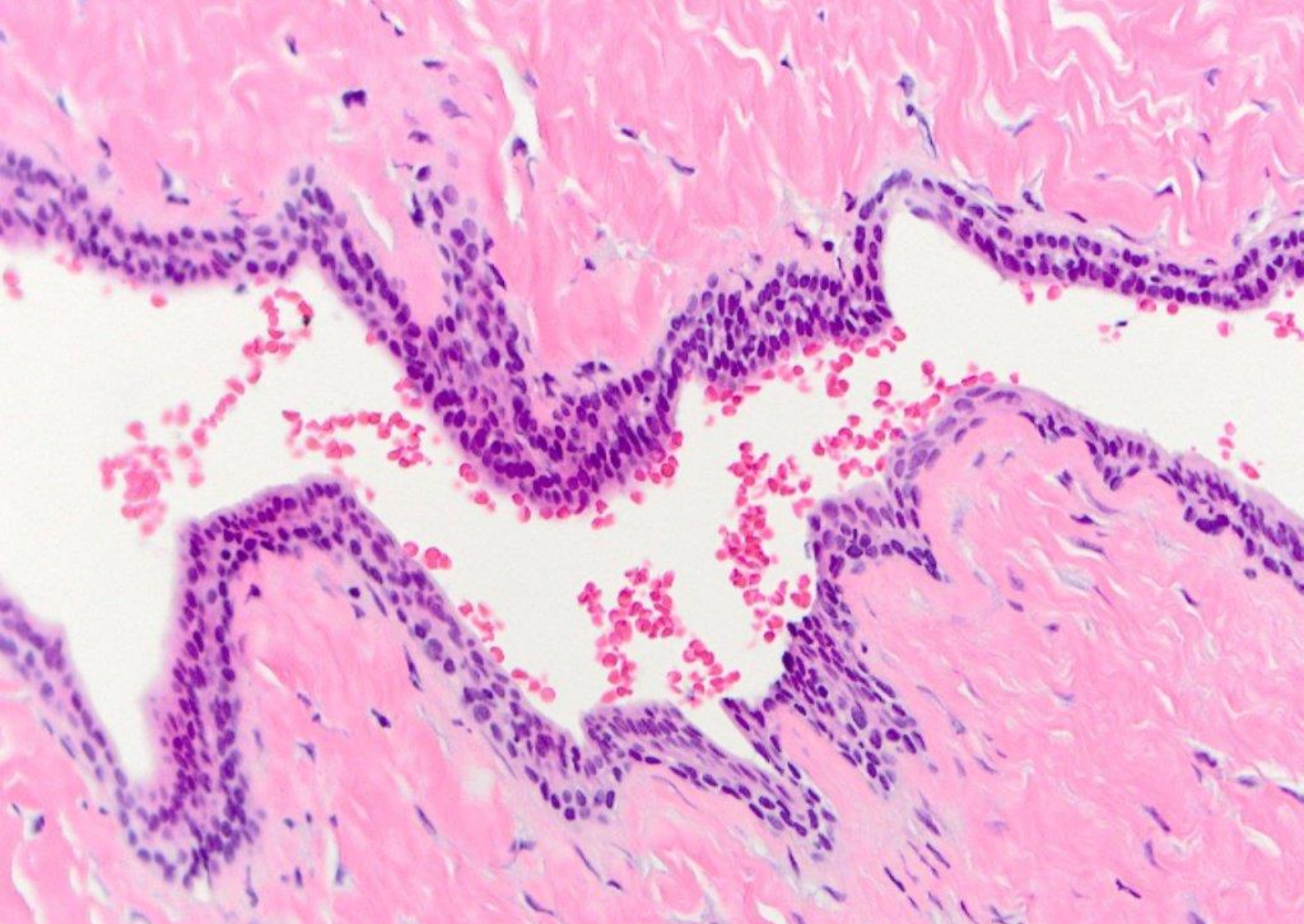




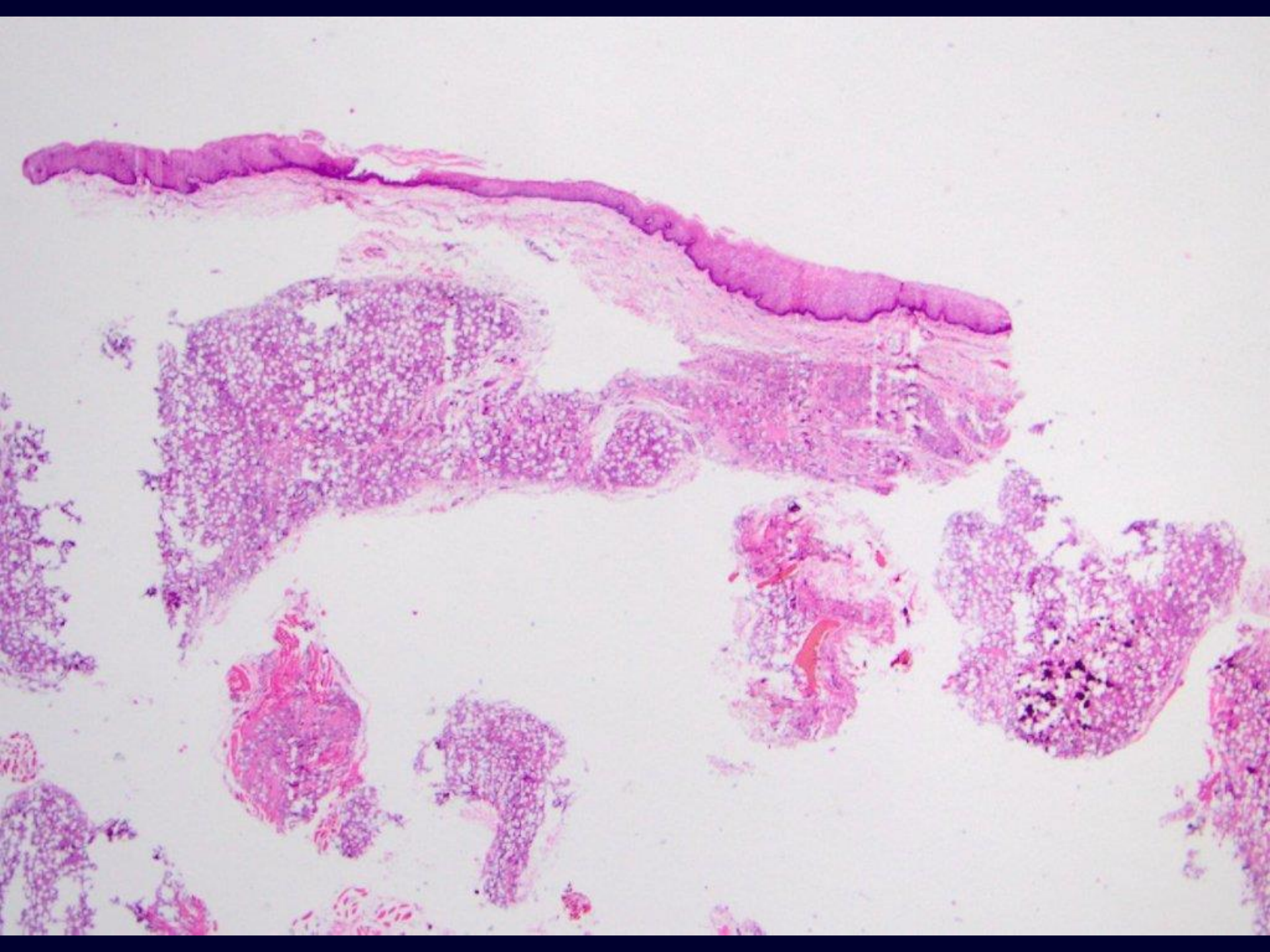
benign mixed tumor

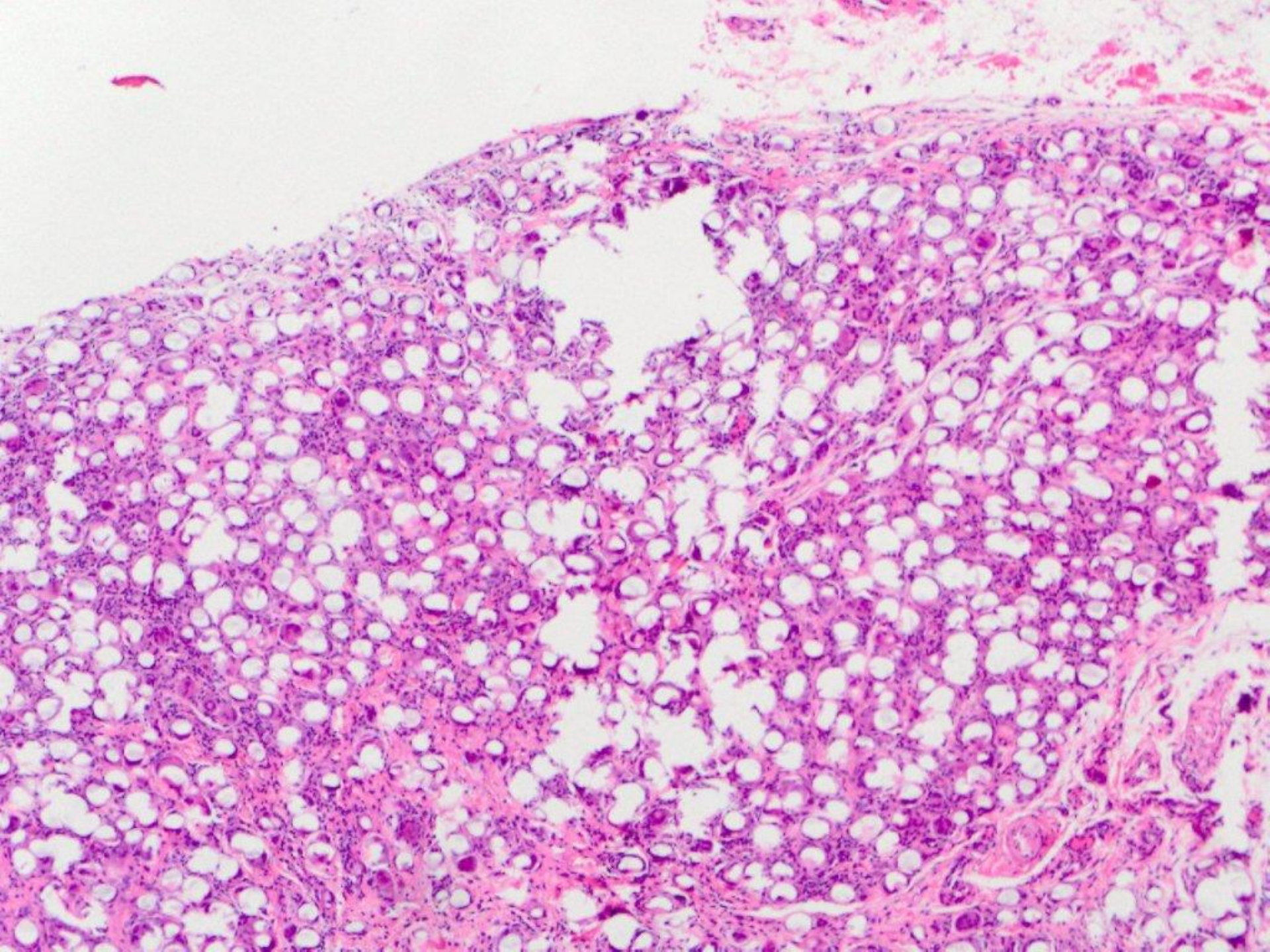


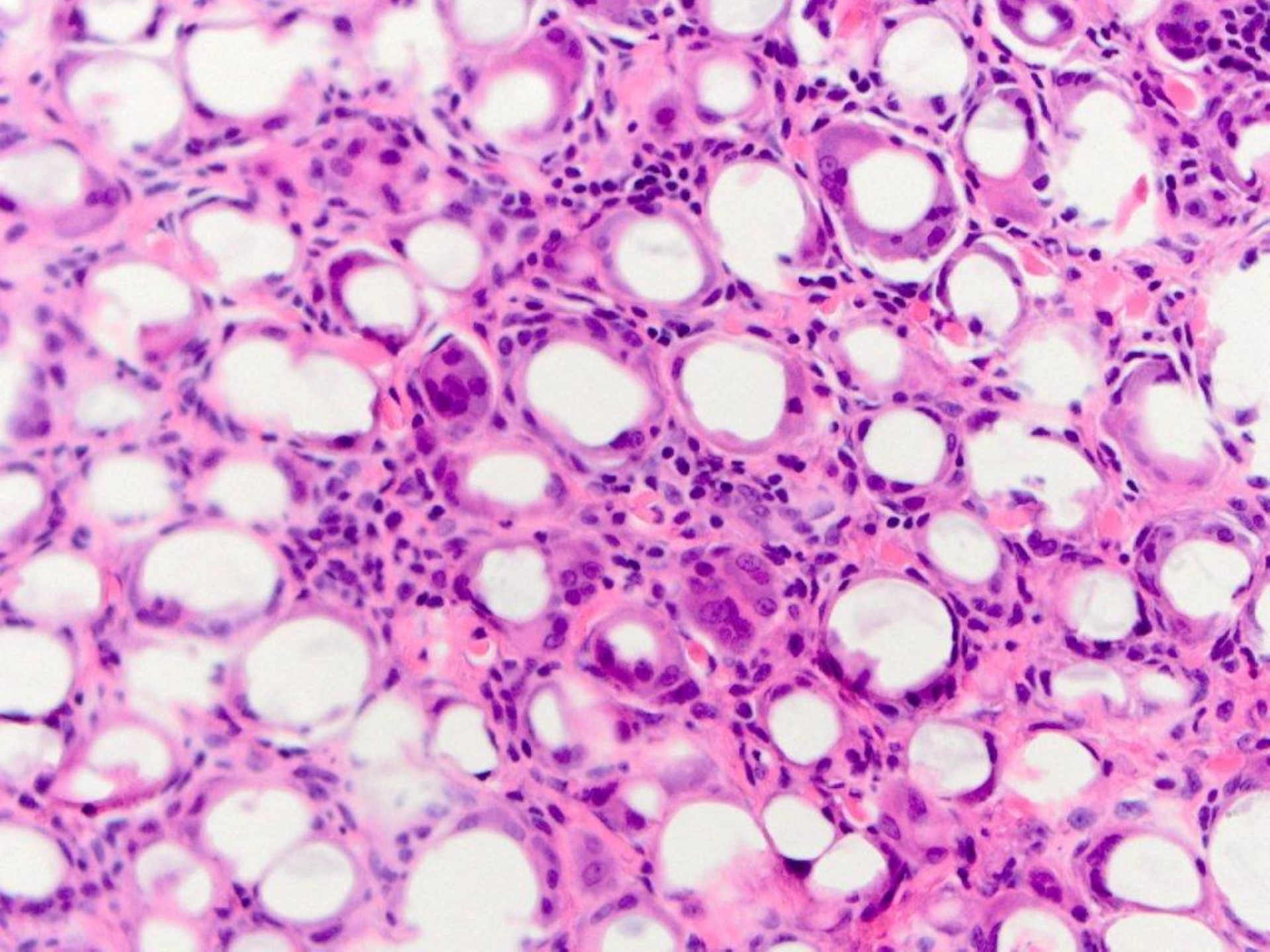


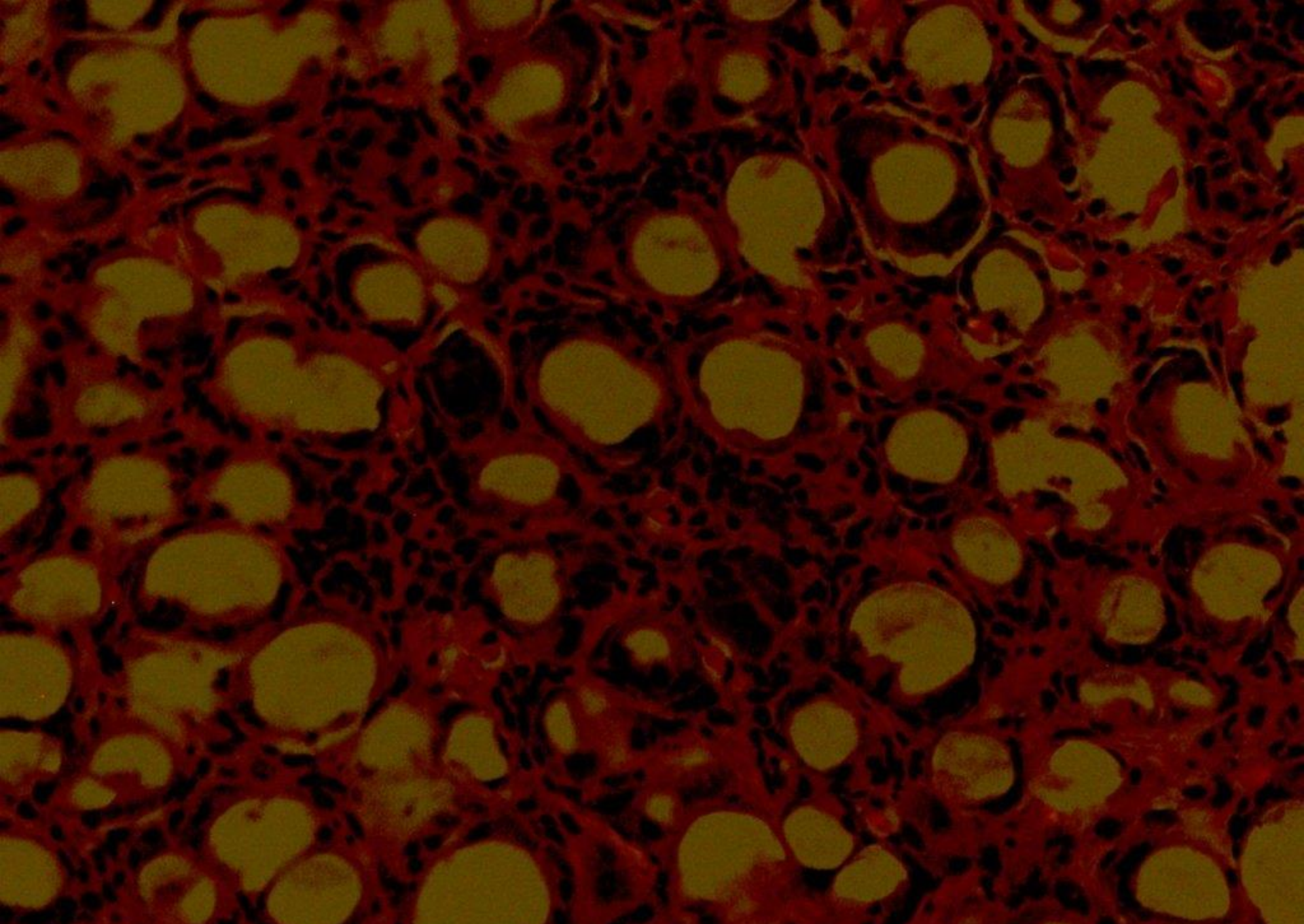


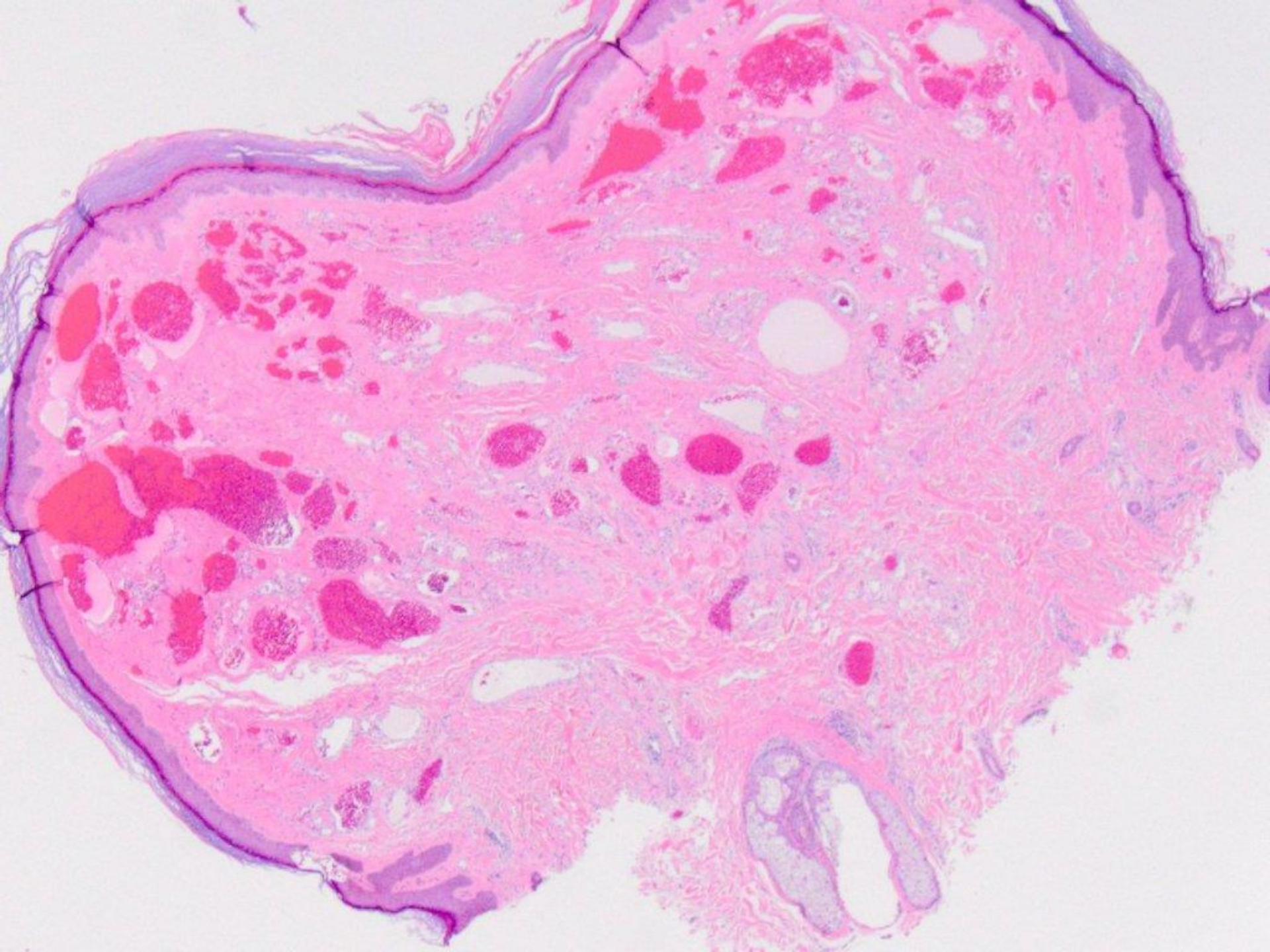
nasopalatine duct cyst

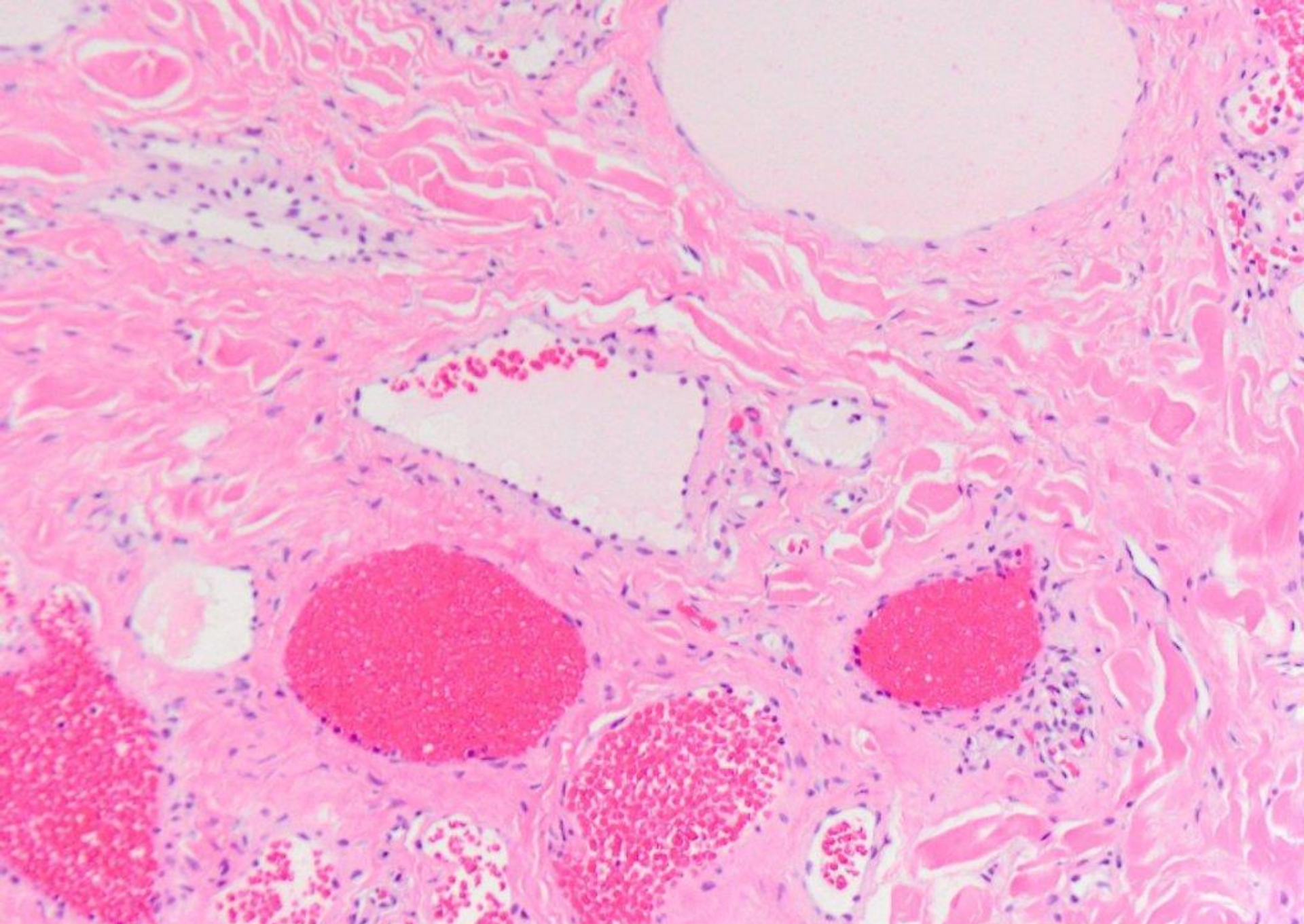




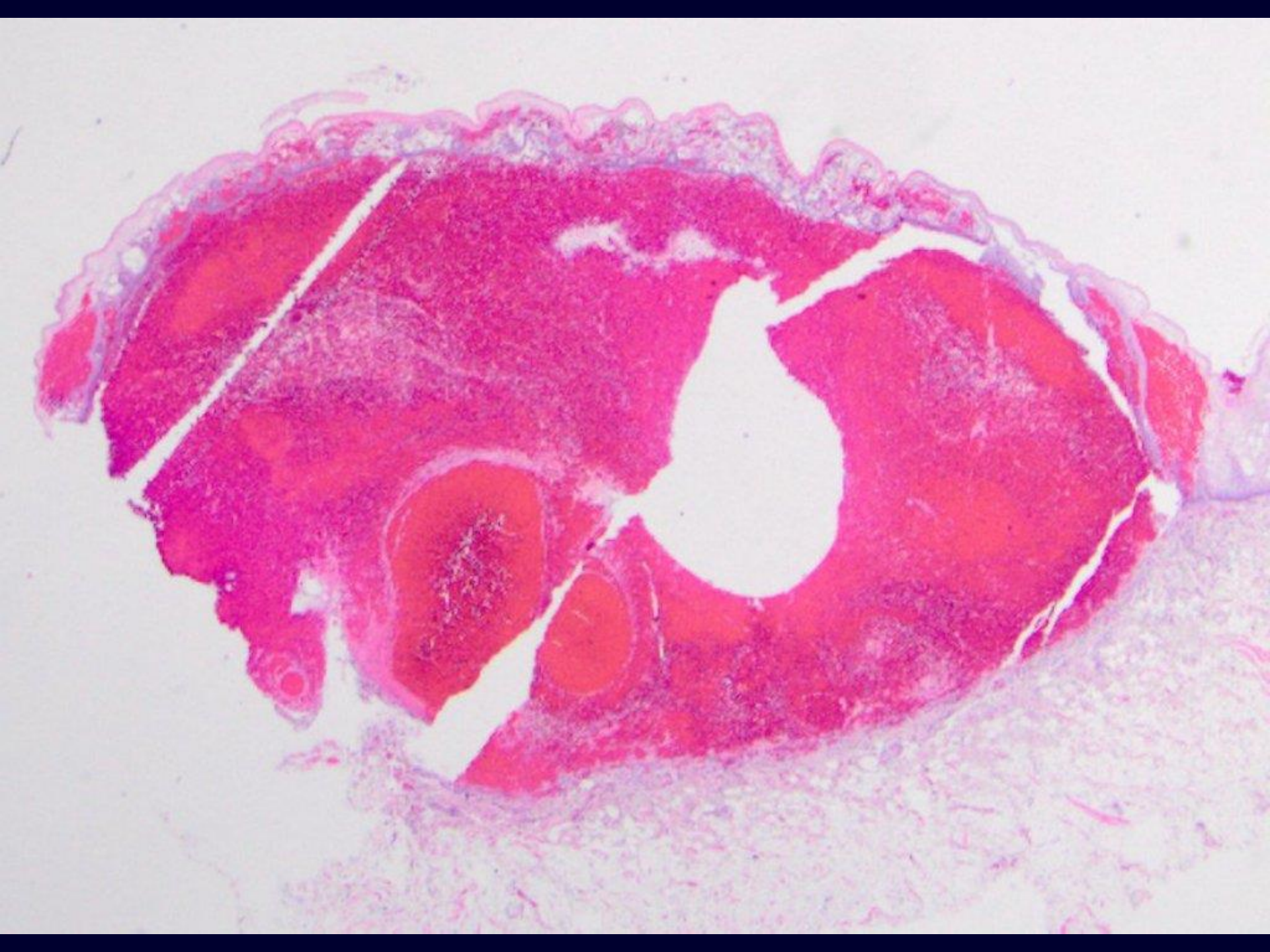


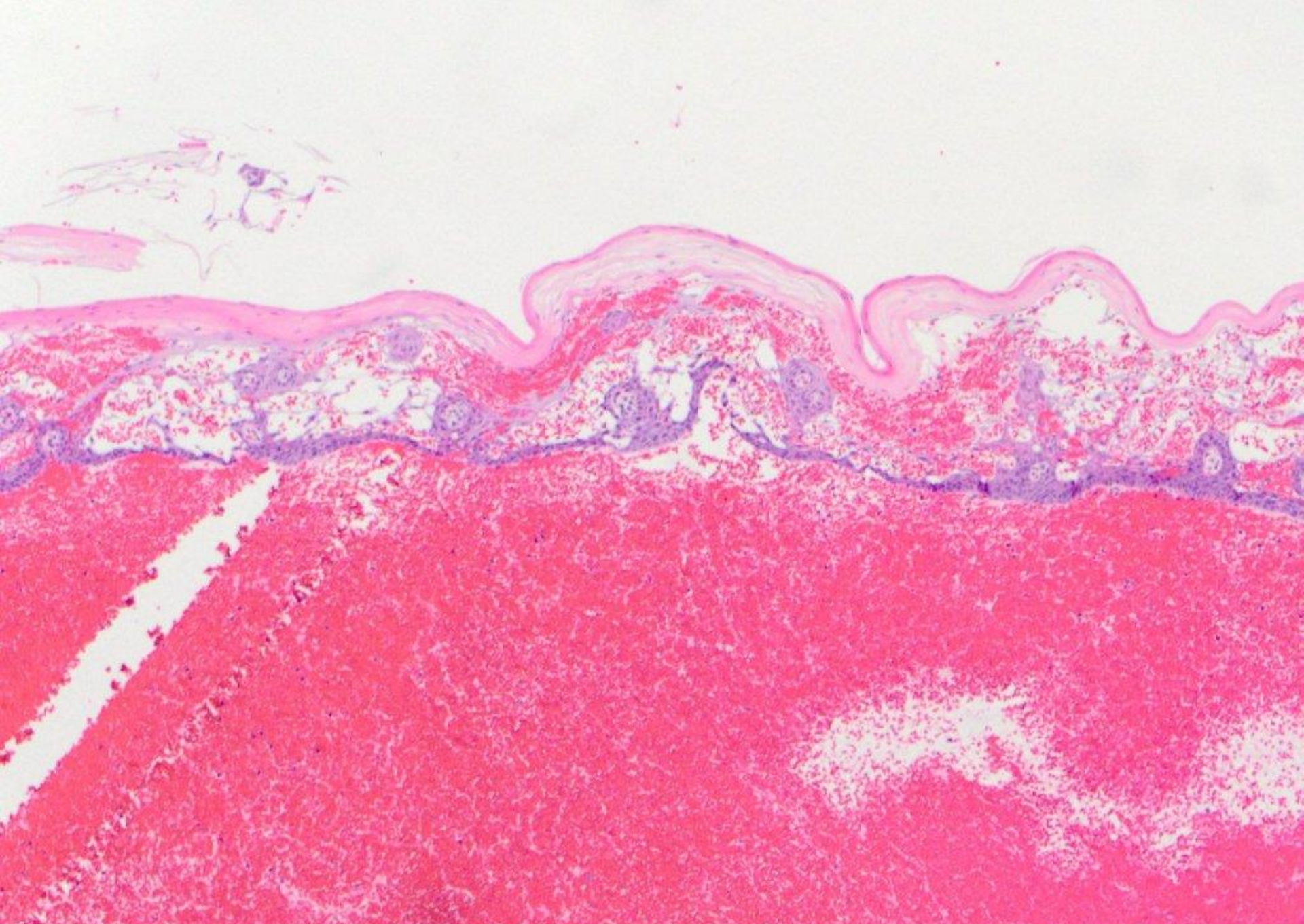




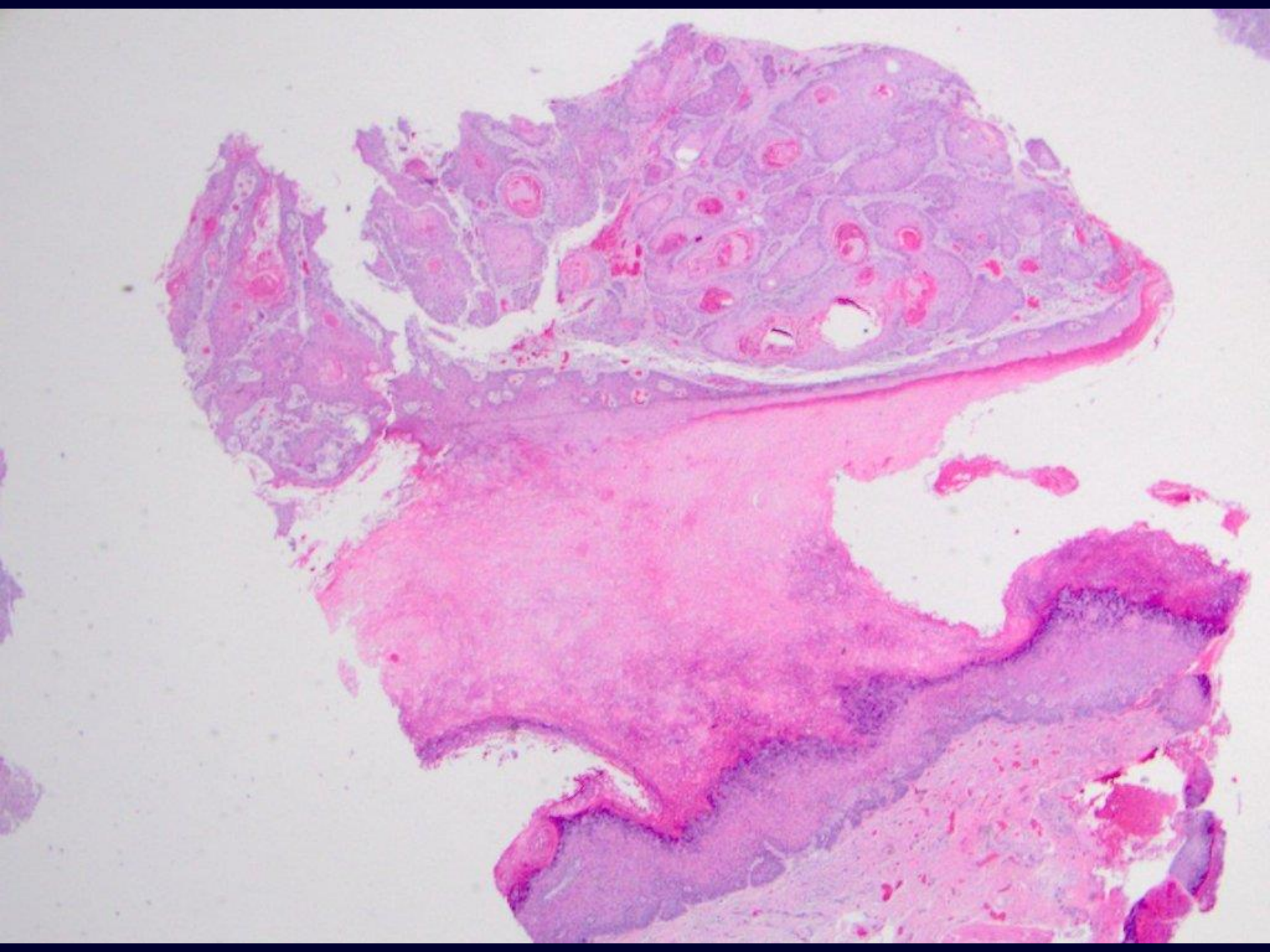


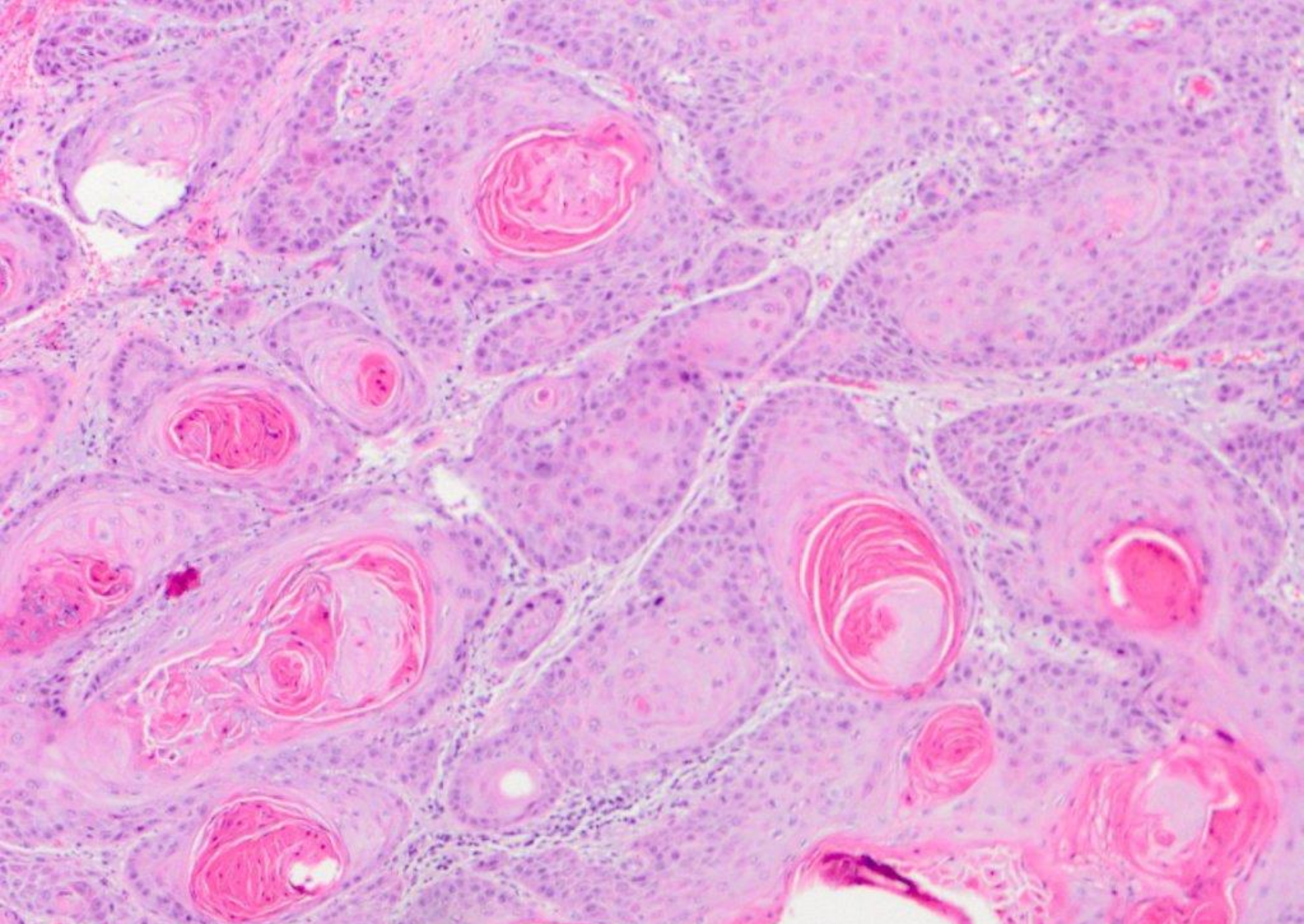
hemangioma



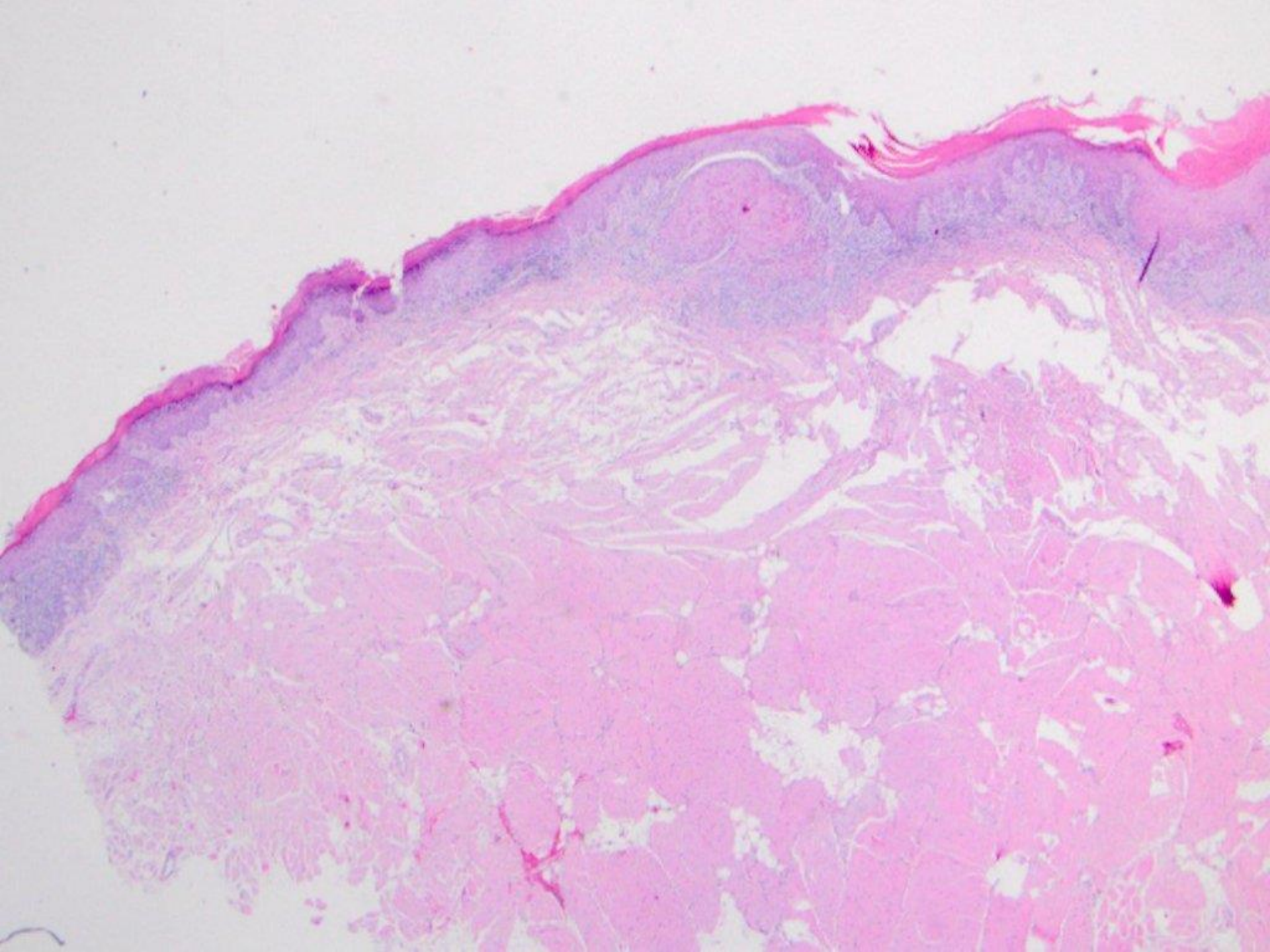


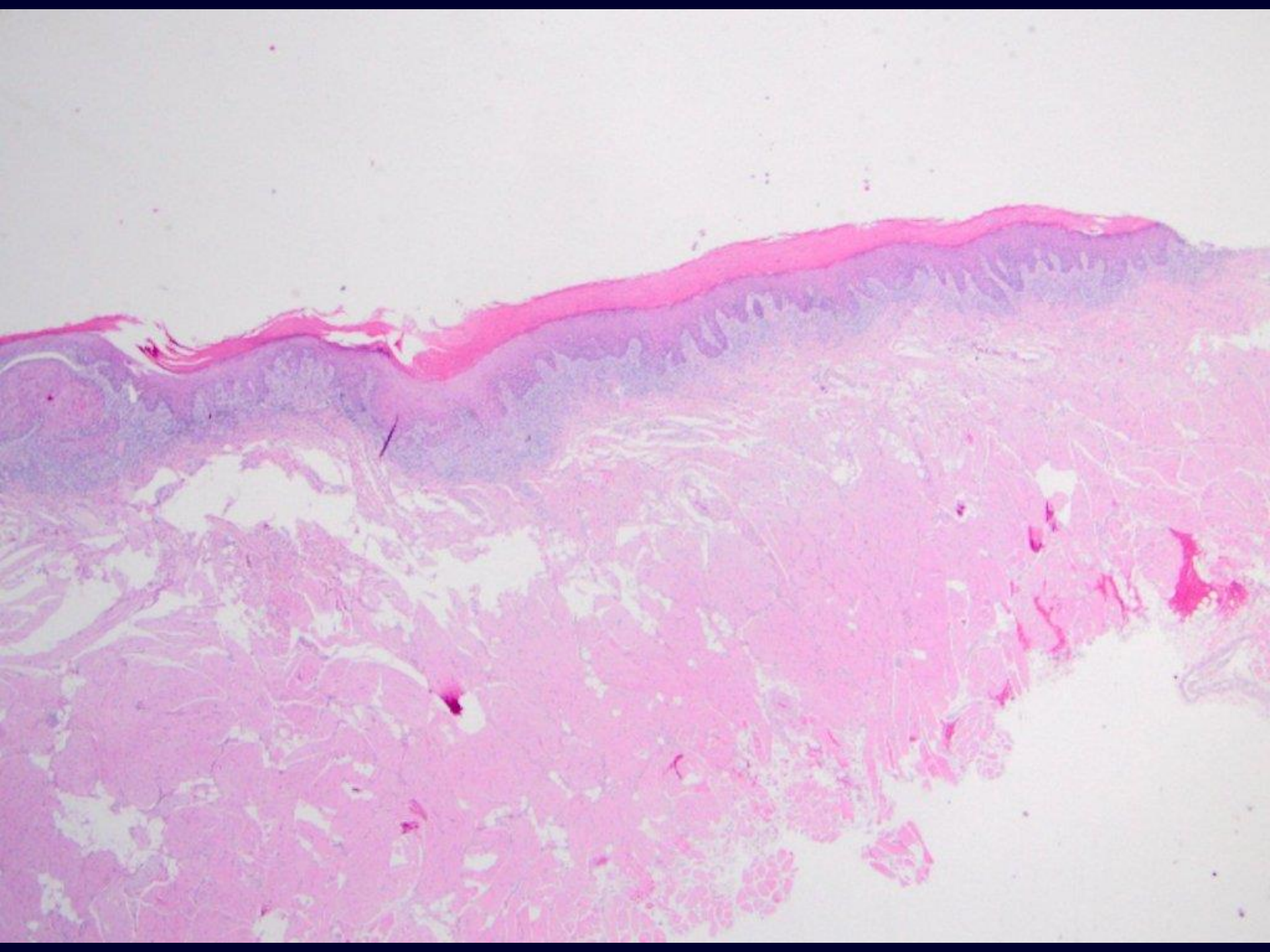
angina bullosa hemorrhagica vs. varix vs ITP

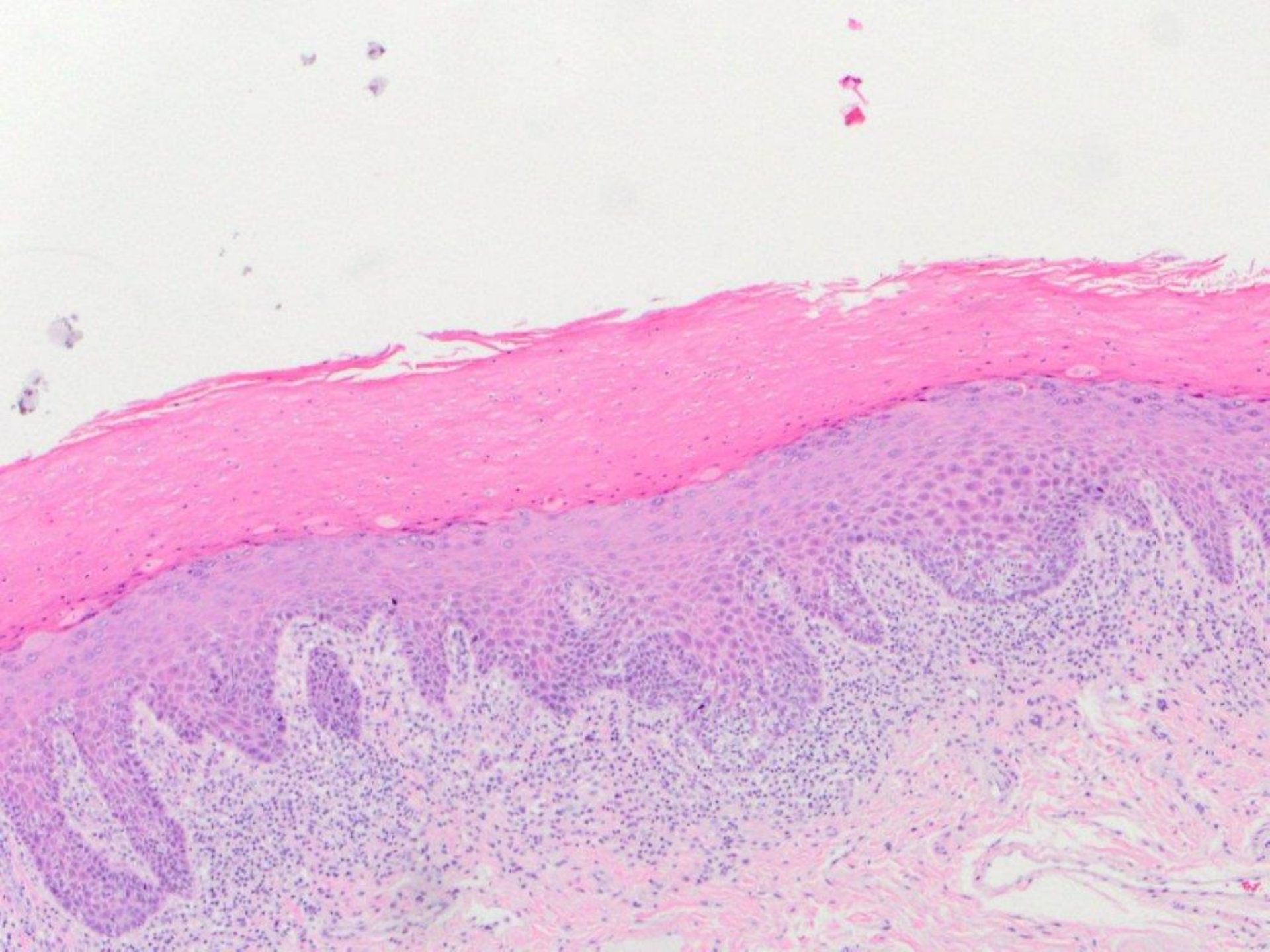


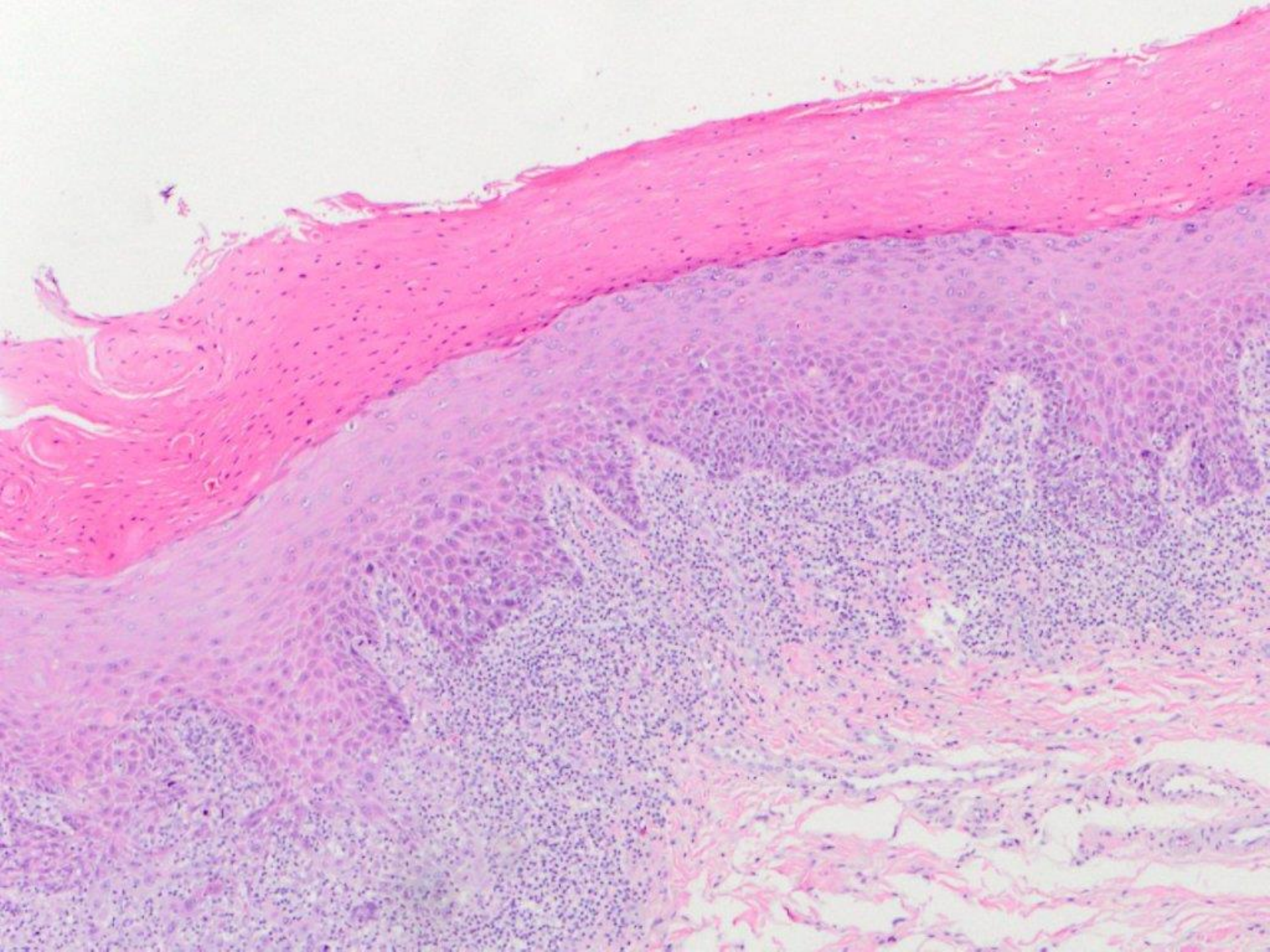


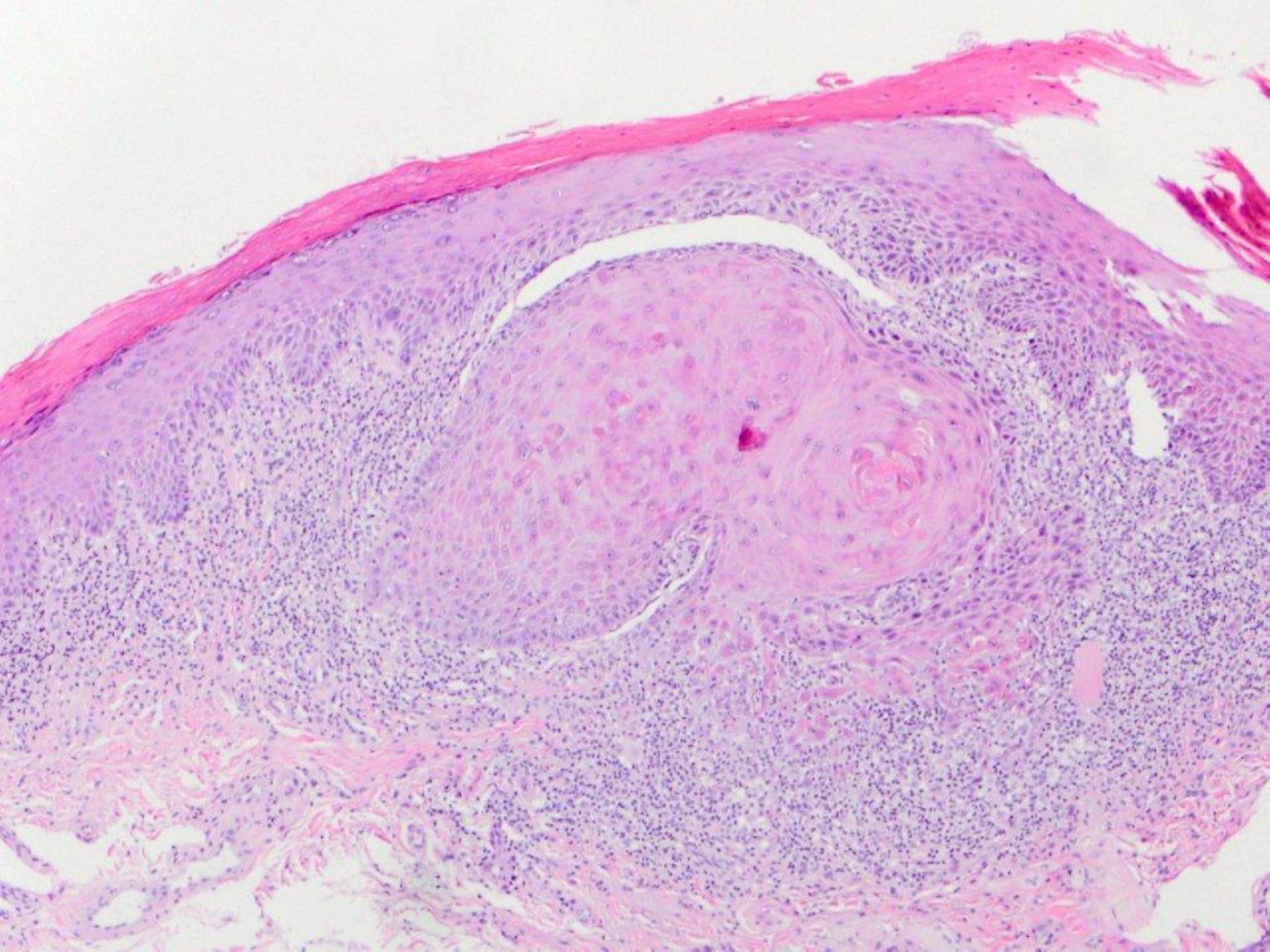
Squamous cell carcinoma

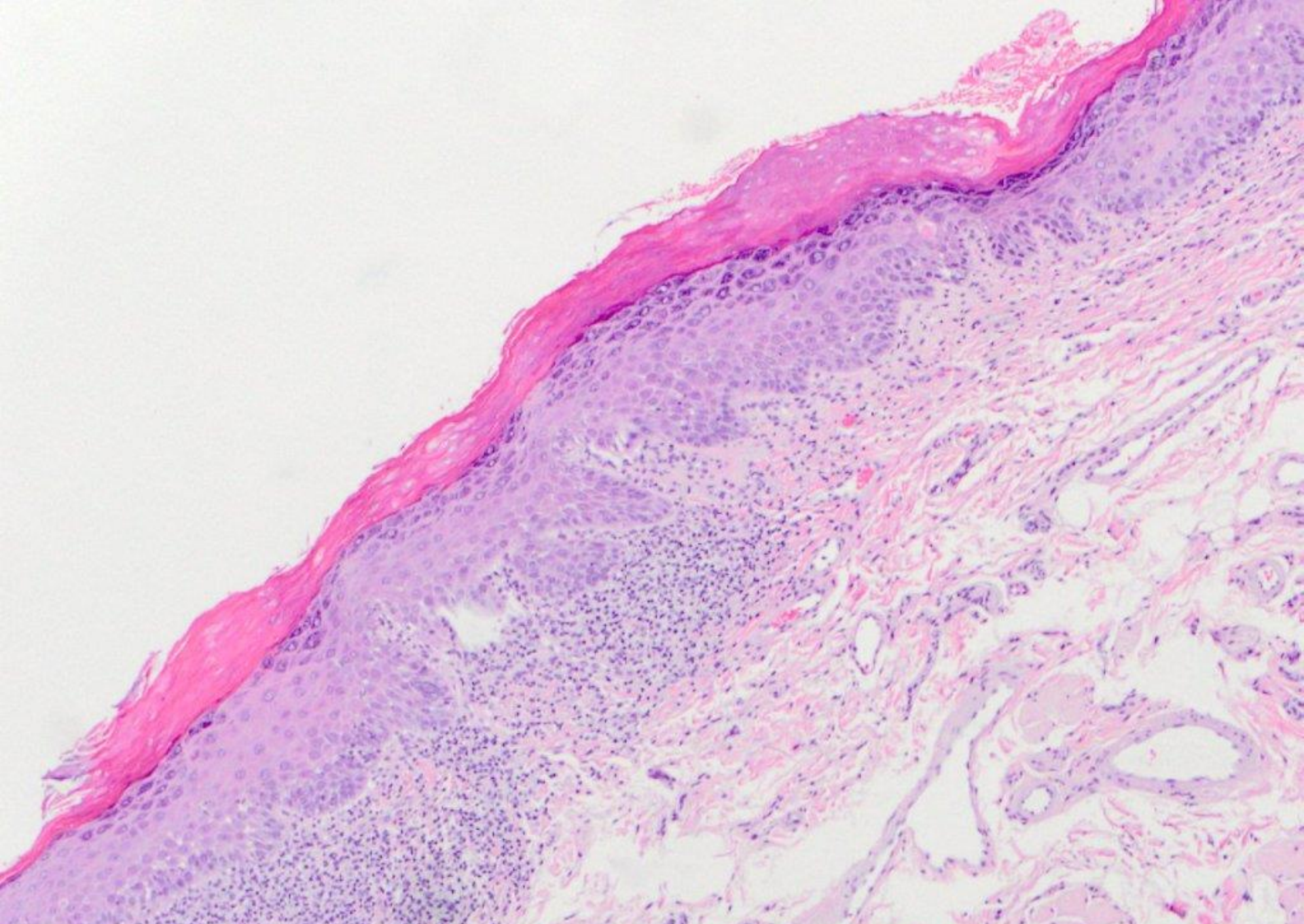




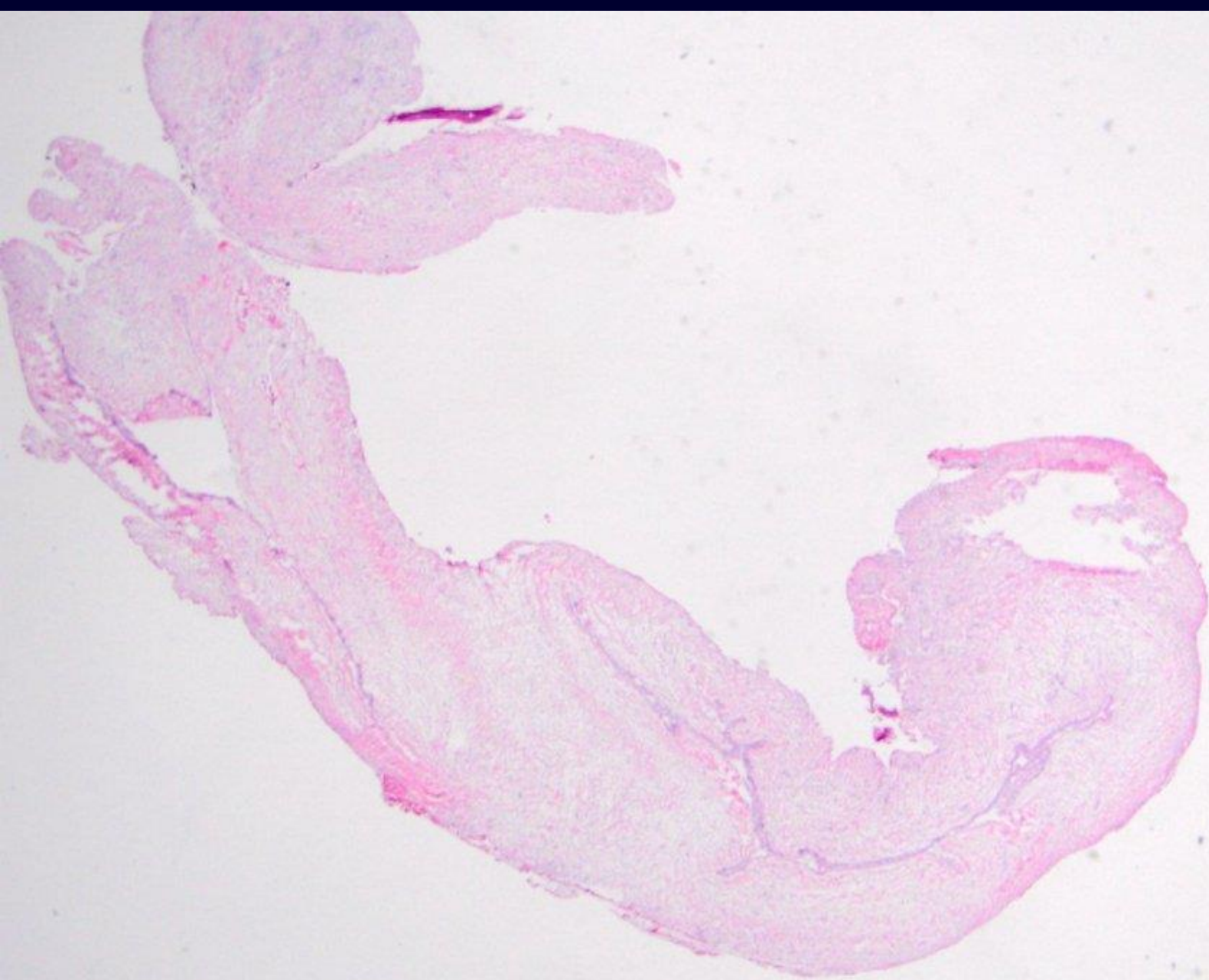


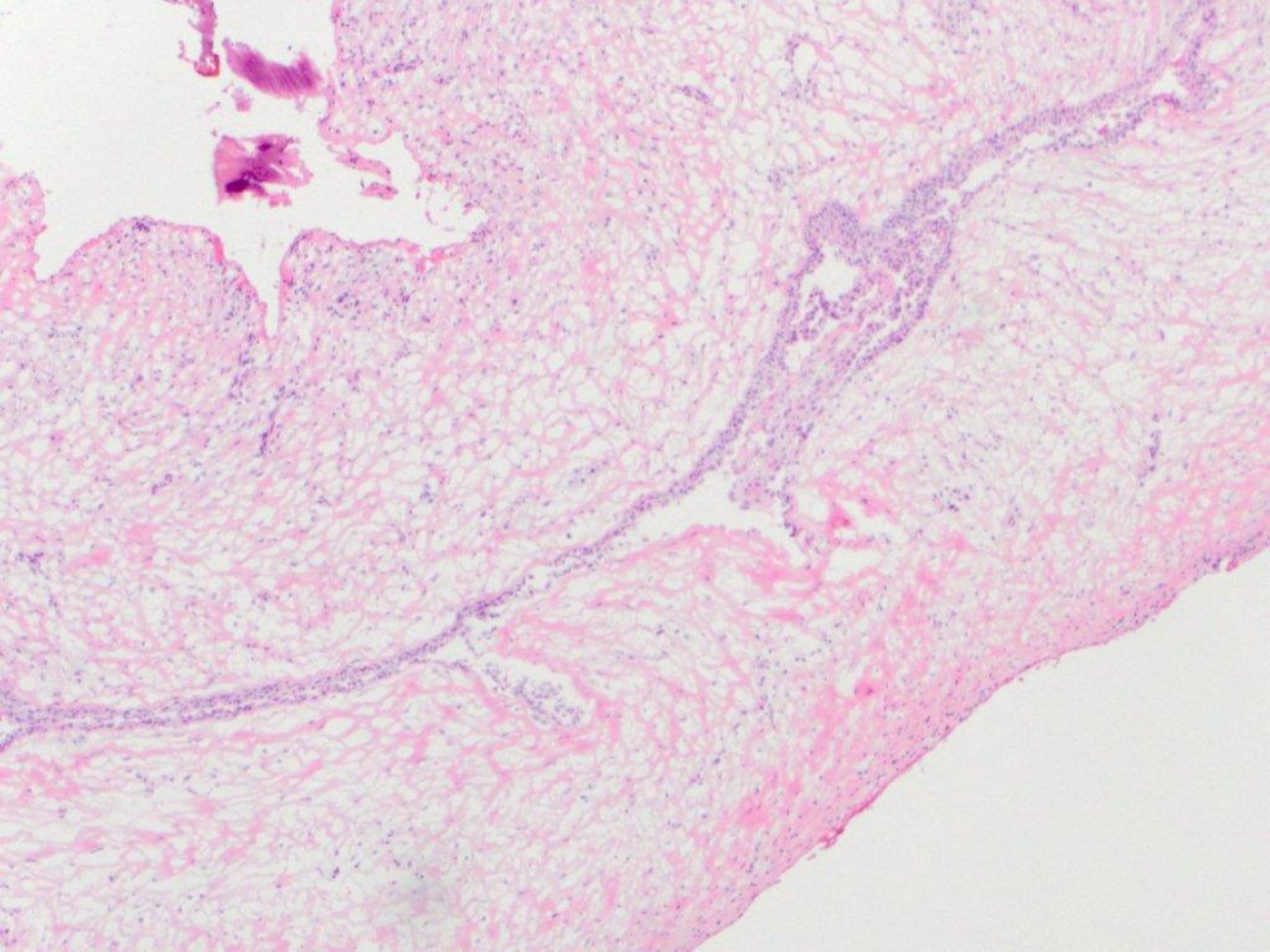


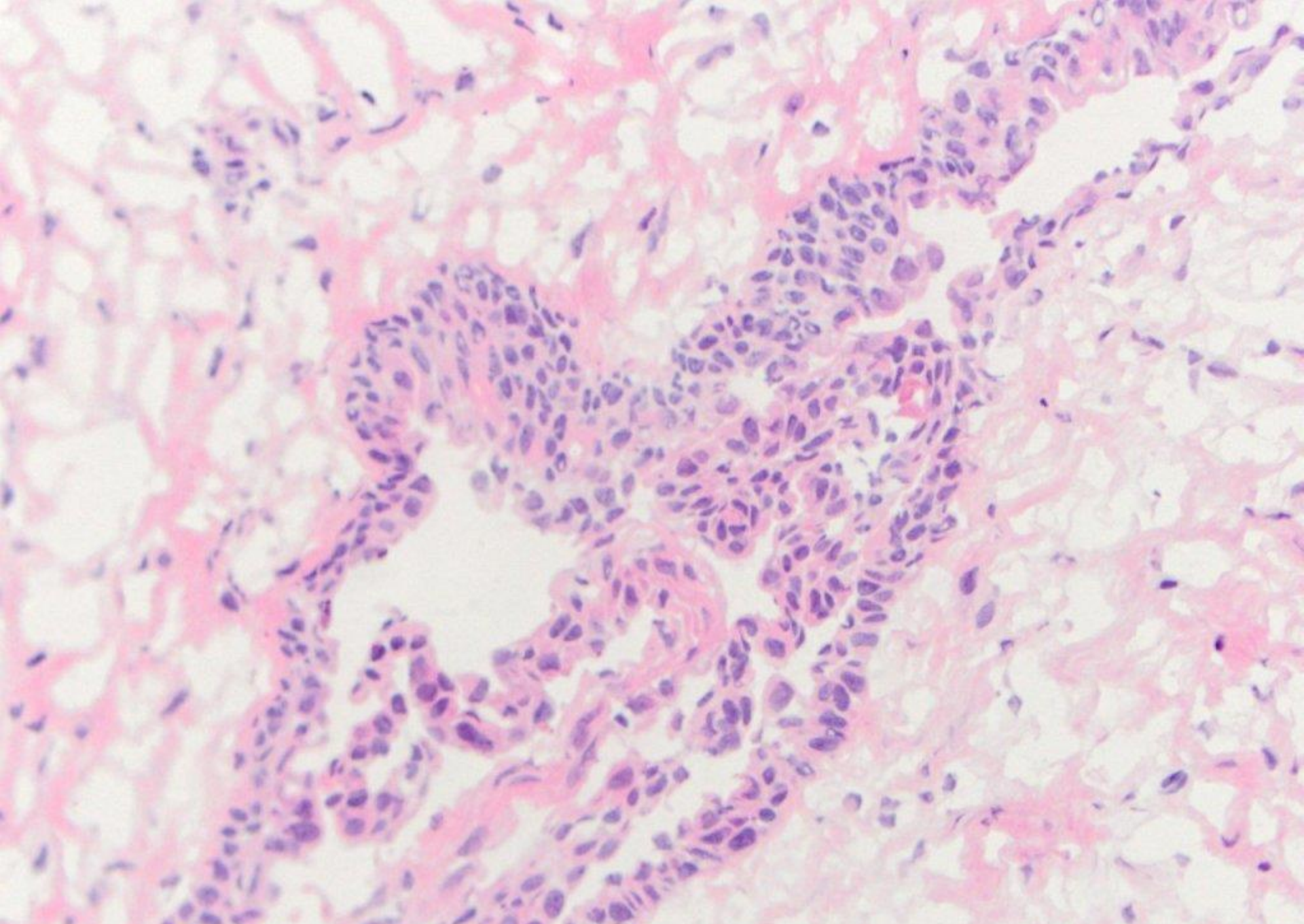




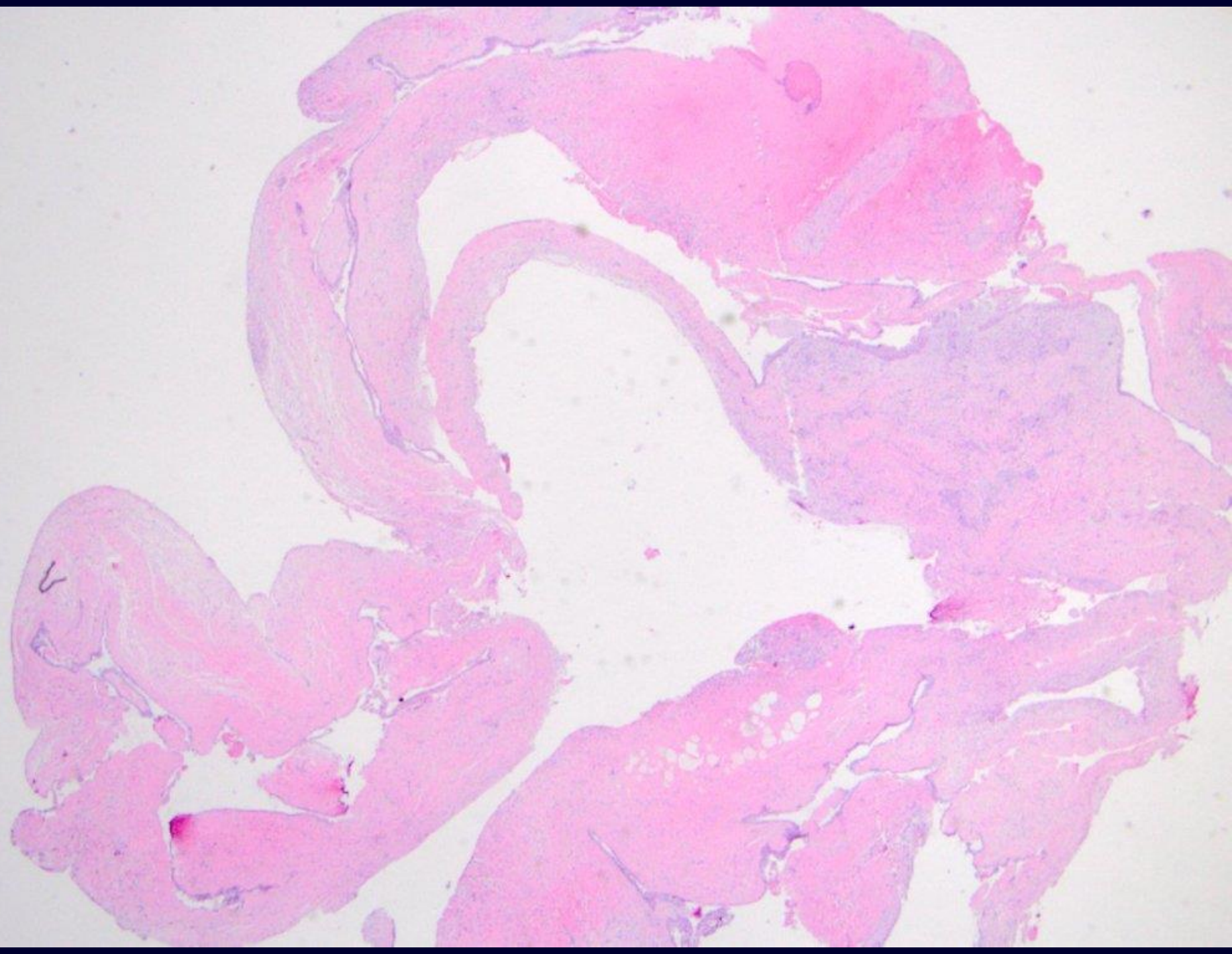
Squamous cell carcinoma

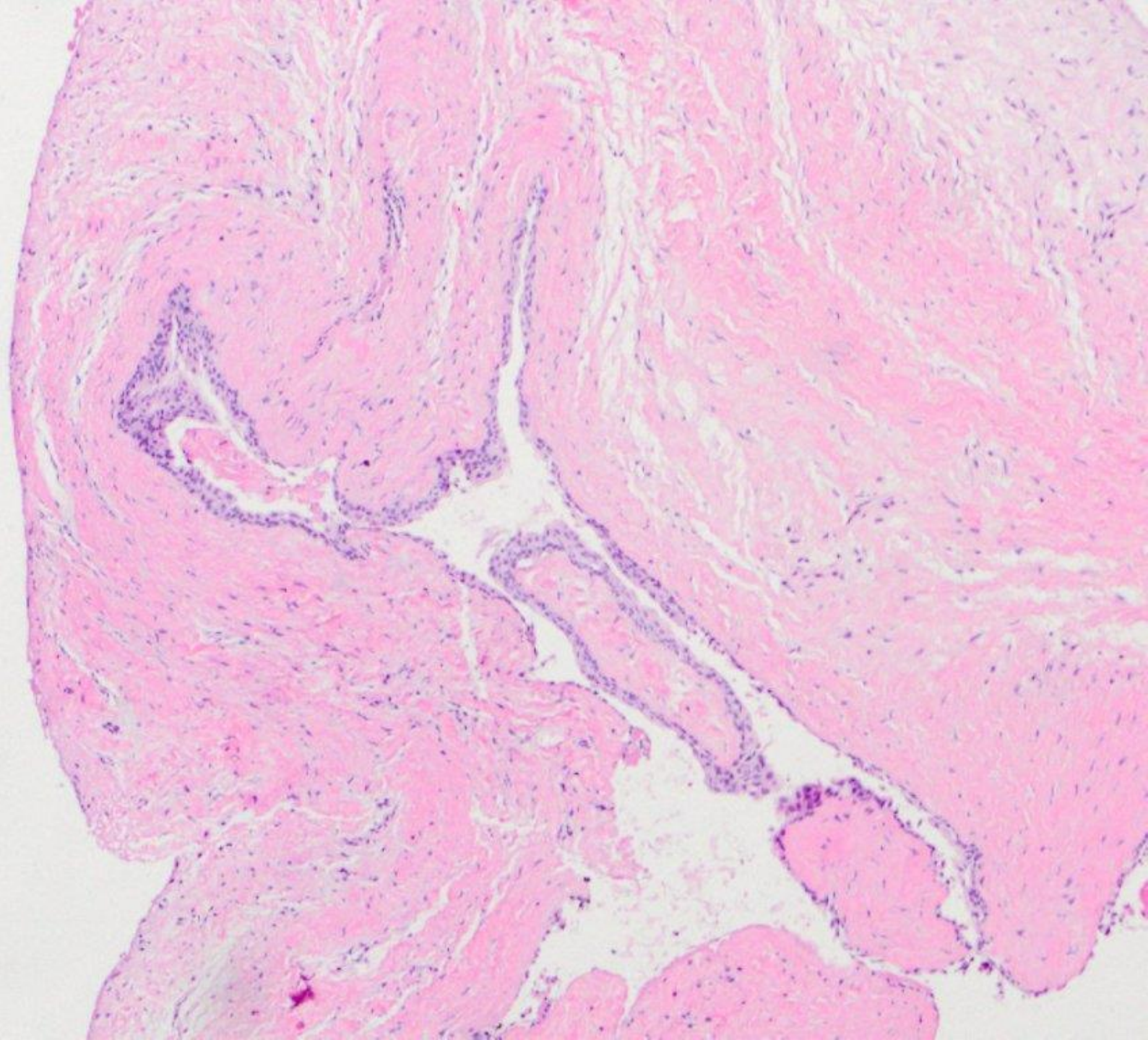


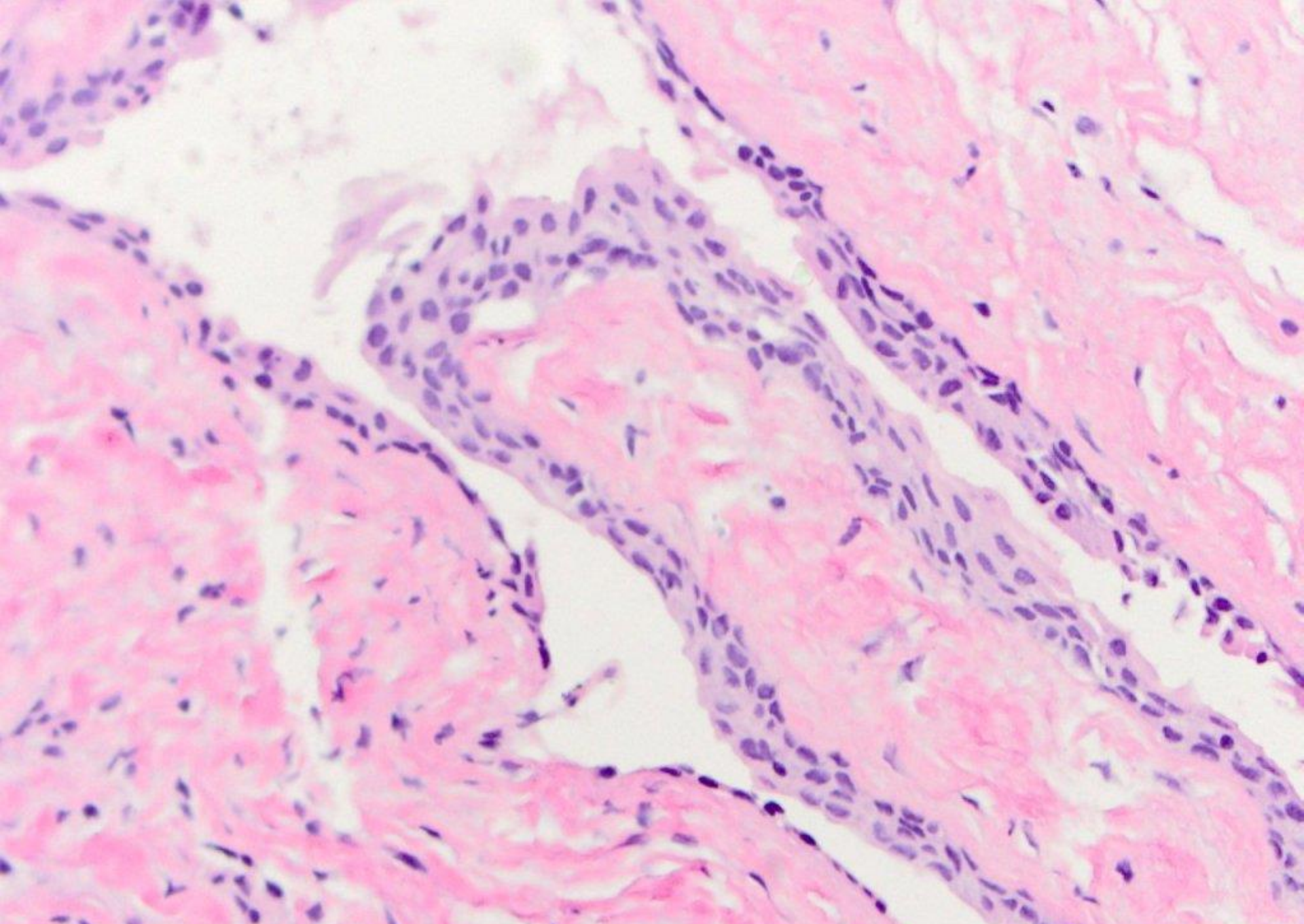




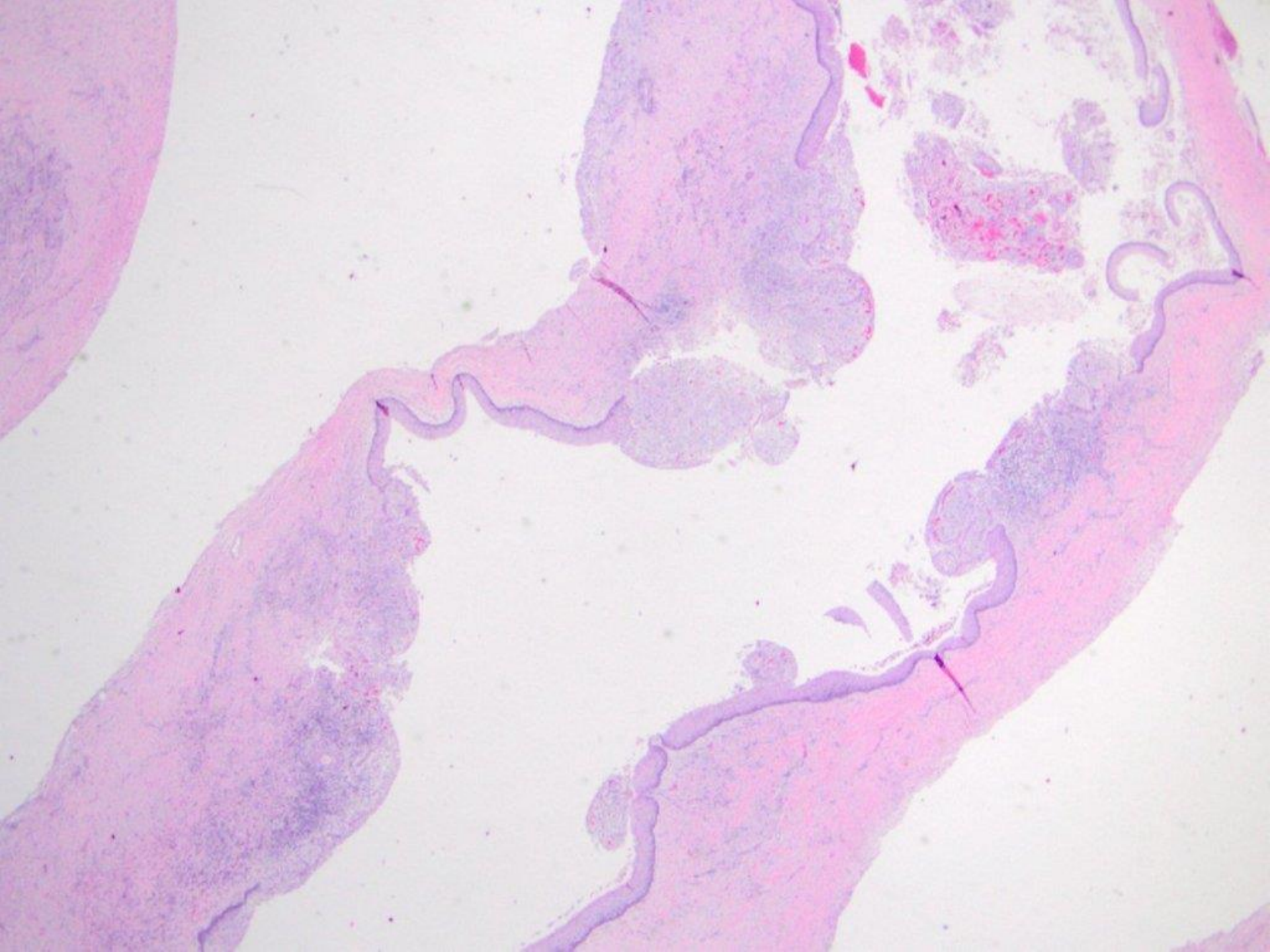
dentigerous cyst (frozen section)

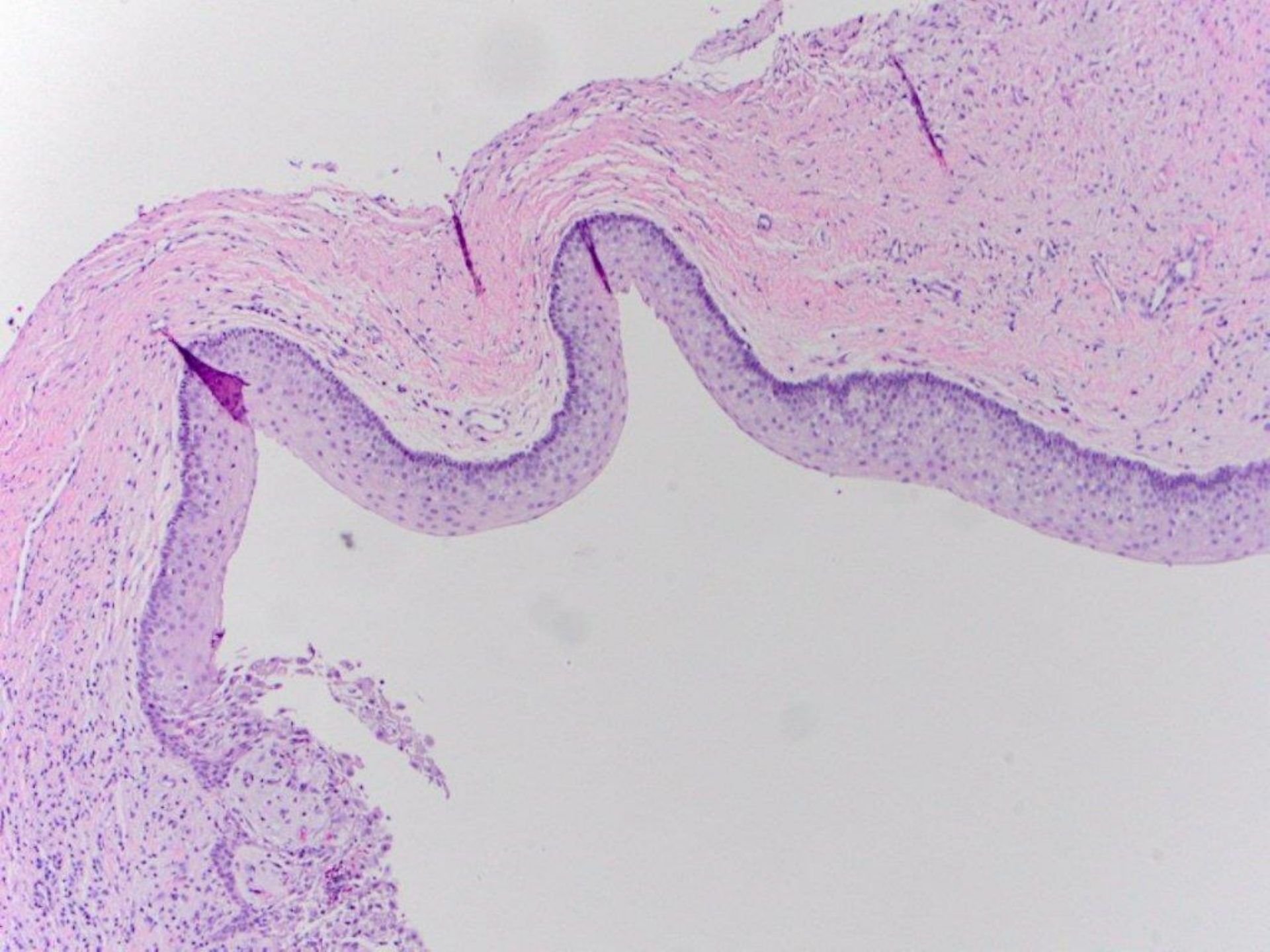


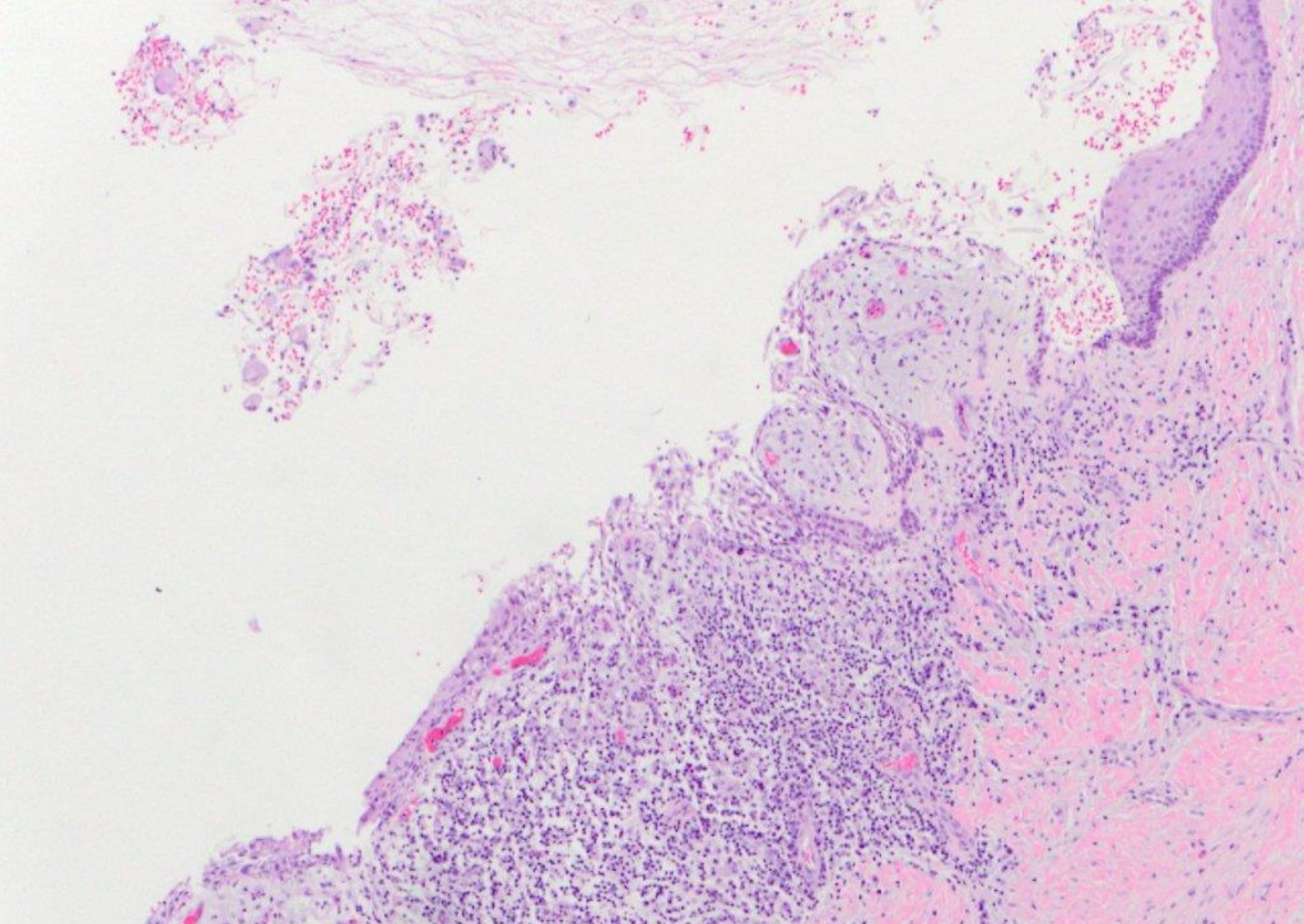




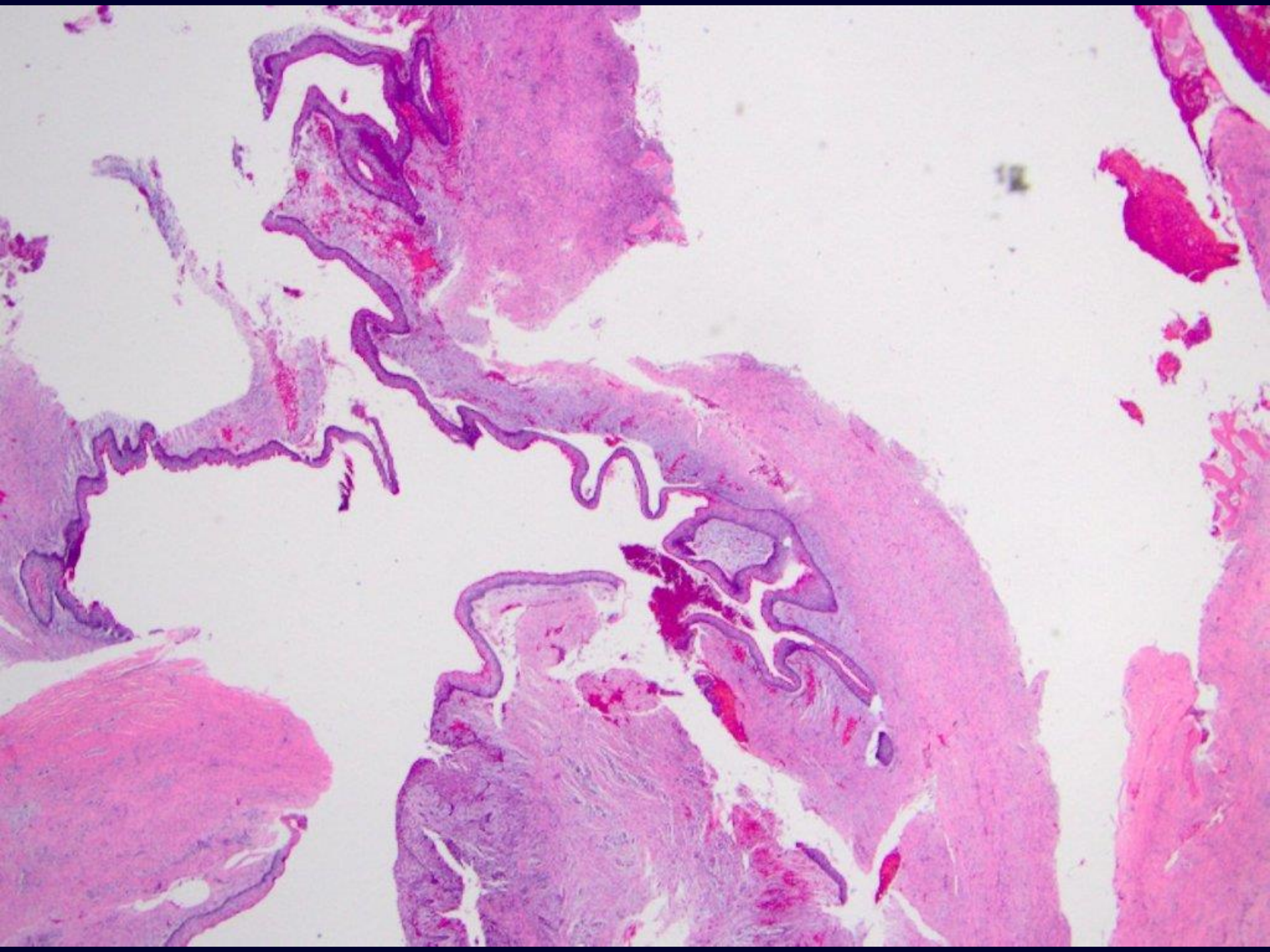
dentigerous cyst (permanent section)

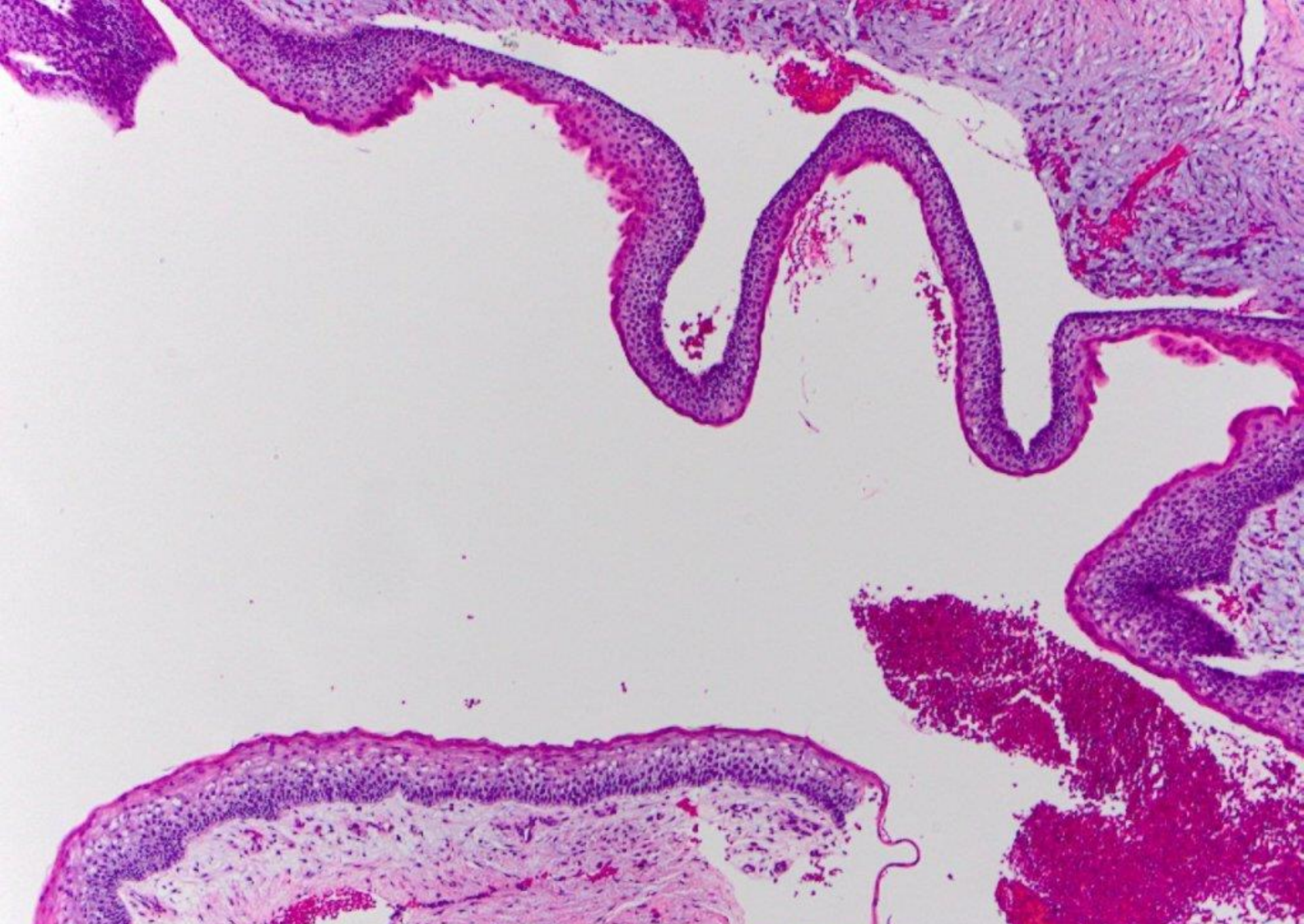






odontogenic keratocyst, focally inflamed





odontogenic keratocyst